

Guidelines on **Testicular Cancer**

P. Albers (Chair), W. Albrecht, F. Algaba,
C. Bokemeyer, G. Cohn-Cedermark, K. Fizazi,
A. Horwich, M.P. Laguna, N. Nicolai, J. Oldenburg

TABLE OF CONTENTS

PAGE

1.	INTRODUCTION	5
	1.1 Aims and scope	5
	1.2 Panel composition	5
	1.2.1 Potential conflict of interest	5
	1.3 Available publications	5
	1.4 Publication history and summary of changes	5
	1.4.1 Publication history	5
	1.4.2 Summary of changes	5
2.	METHODS	7
	2.1 Review	7
3.	EPIDEMIOLOGY, AETIOLOGY AND PATHOLOGY	7
	3.1 Epidemiology	7
	3.2 Pathological classification	7
4.	STAGING AND CLASSIFICATION SYSTEMS	8
	4.1 Diagnostic tools	8
	4.2 Serum tumour markers: post-orchietomy half-life kinetics	8
	4.3 Retroperitoneal, mediastinal and supraclavicular lymph nodes and viscera	8
	4.4 Staging and prognostic classifications	9
5.	DIAGNOSTIC EVALUATION	12
	5.1 Clinical examination	12
	5.2 Imaging of the testis	13
	5.3 Serum tumour markers at diagnosis	13
	5.4 Inguinal exploration and orchietomy	13
	5.5 Organ-sparing surgery	13
	5.6 Pathological examination of the testis	13
	5.7 Diagnosis and treatment of testicular intraepithelial neoplasia (TIN)	14
	5.8 Screening	14
	5.9 Guidelines for the diagnosis and staging of testicular cancer	14
6.	PROGNOSIS	15
	6.1 Risk factors for metastatic relapse in stage I GCT	15
7.	DISEASE MANAGEMENT	15
	7.1 Impact on fertility and fertility-associated issues	15
	7.2 Stage I Germ cell tumours	15
	7.2.1 Stage I seminoma	15
	7.2.1.1 Surveillance	15
	7.2.1.2 Adjuvant chemotherapy	16
	7.2.1.3 Adjuvant radiotherapy and risk-adapted treatment	16
	7.2.1.4 Risk-adapted treatment	16
	7.2.1.5 Retroperitoneal lymph node dissection (RPLND)	16
	7.2.2 Guidelines for the treatment of seminoma stage I	16
	7.3 NSGCT clinical stage I	16
	7.3.1 Surveillance	17
	7.3.2 Adjuvant chemotherapy	17
	7.3.3 Risk-adapted treatment	17
	7.3.4 Retroperitoneal lymph node dissection	18
	7.3.5 Guidelines for the treatment of NSGCT stage I	18
	7.3.6 Risk-adapted treatment for CS1 based on vascular invasion	19
	7.4 Metastatic germ cell tumours	20
	7.4.1. CS1S with (persistently) elevated serum tumour markers	20
	7.4.2 Metastatic disease (stage IIA/B)	20
	7.4.2.1 Stage IIA/B seminoma	20
	7.4.2.2 Stage IIA/B non-seminoma	21
	7.4.3 Metastatic disease (stage IIC and III)	22

	7.4.3.1	Primary chemotherapy	22
	7.4.3.1.1	Good prognosis risk group - SGCT	22
	7.4.3.1.2	Intermediate prognosis risk group - SGCT	22
	7.4.3.1.3	Good prognosis risk group - NSGCT	22
	7.4.3.1.4	Intermediate prognosis risk group - NSGCT	23
	7.4.3.1.5	Poor prognosis risk group - NSGCT	23
7.5		Restaging and further treatment	23
	7.5.1	Restaging	23
	7.5.2	Residual tumour resection	24
	7.5.2.1	Seminoma	24
	7.5.2.2	Non-seminoma	24
	7.5.3	Timing of surgery in the case of multiple sites	25
	7.5.3.1	Quality and intensity of surgery	25
	7.5.3.2	Salvage and desperation surgery.	25
	7.5.3.3	Consolidation chemotherapy after secondary surgery	25
	7.5.4	Systemic salvage treatment for relapse or refractory disease	25
	7.5.5	Second relapse	27
	7.5.5.1	Late relapse (≥ 2 years after end of first-line treatment)	27
	7.5.5.2	Treatment of brain metastases	27
	7.5.6	Guidelines for the treatment of metastatic germ cell tumours	28
8.		FOLLOW-UP AFTER CURATIVE THERAPY	28
	8.1	Follow-up care for cancer patients	28
	8.2	General considerations	28
	8.3	Follow-up: stage I non-seminoma	29
	8.3.1	Follow-up investigations during surveillance	29
	8.3.2	Follow-up after nerve-sparing RPLND	29
	8.3.3	Follow-up after adjuvant chemotherapy	30
	8.4	Follow-up: stage I seminoma	30
	8.4.1	Follow-up after radiotherapy	30
	8.4.2	Follow-up during surveillance	30
	8.4.3	Follow-up after adjuvant chemotherapy	31
	8.5	Follow-up: (metastatic) disease	31
	8.6	Quality of life and long-term toxicities after cure for testicular cancer	31
	8.6.1	Second malignant neoplasms (SMN)	32
	8.6.2	Leukaemia	32
	8.6.3	Infections	32
	8.6.4	Pulmonary complications	32
	8.6.5	Cardiovascular toxicity	32
	8.6.6	Raynaud-like phenomena	32
	8.6.7	Neurotoxicity	32
	8.6.8	Ototoxicity	32
	8.6.9	Nephrotoxicity	33
	8.6.10	Hypogonadism	33
	8.6.11	Fatigue	33
	8.6.12	Quality of life	33
9.		TESTICULAR STROMAL TUMOURS	33
	9.1	Classification	33
	9.2	Leydig cell tumours	33
	9.2.1	Epidemiology	33
	9.2.2	Pathology of Leydig cell tumours	33
	9.2.3	Diagnosis	34
	9.3	Sertoli cell tumours	34
	9.3.1	Epidemiology	34
	9.3.2	Pathology of Sertoli cell tumours	34
	9.3.2.1	Classification	34
	9.3.3	Diagnosis	34
	9.4	Treatment of Leydig- and Sertoli cell tumours	35
	9.5	Follow-up of Leydig- and Sertoli cell tumours	35

9.6	Granulosa cell tumour	35
9.7	Thecoma/fibroma group of tumours	35
9.8	Other sex cord/gonadal stromal tumours	35
9.9	Tumours containing germ cell and sex cord/gonadal stroma (gonadoblastoma)	36
9.10	Miscellaneous tumours of the testis	36
9.10.1	Tumours of ovarian epithelial types	36
9.10.2	Tumours of the collecting ducts and rete testis	36
9.10.3	Tumours (benign and malignant) of non-specific stroma	36
10.	REFERENCES	36
11.	CONFLICT OF INTEREST	60

1. INTRODUCTION

1.1 Aims and scope

The aim of these guidelines is to present the current evidence for the diagnosis and treatment of patients with cancer of the testis. Testicular cancer represents 5% of urological tumours affecting mostly younger males. This document addresses germ-cell tumours and sex cord/gonadal stromal tumours.

1.2 Panel composition

The EAU Guidelines Panel on Testicular Cancer consists of a multidisciplinary group of clinicians, including urologists, a pathologist, oncologists and radiotherapists. Members of this panel have been selected based on their expertise to represent the professionals treating patients suspected of harbouring testis cancer.

1.2.1 Potential conflict of interest

All experts involved in the production of this document have submitted potential conflict of interest statements.

1.3 Available publications

A quick reference document (Pocket guidelines) is available, both in print and in a number of versions for mobile devices. These are abridged versions which may require consultation together with the full text versions. Several scientific publications are available as are a number of translations of all versions of the EAU Testicular Cancer Guidelines. All documents can be viewed, free access, through the EAU website Uroweb: <http://www.uroweb.org/guidelines/online-guidelines/>.

1.4 Publication history and summary of changes

1.4.1 Publication history

The European Association of Urology (EAU) published the first guidelines on Testicular Cancer in 2001. Since 2008, the Testicular Guidelines contain a separate chapter on testicular stromal tumours. This document presents a limited update of the 2014 publication. Review papers have been published in the society scientific journal European Urology, the latest version dating to 2011 [1].

1.4.2 Summary of changes

The literature in the entire document has been assessed and updated, whenever relevant.

Key changes for this 2015 print:

- A new flowchart (Figure 2) on Treatment options in patient with seminoma clinical state IIA and IIB has been included.
- A new section on Quality of life and long-term toxicities after cure for testicular cancer was added (Section 8.6).

Conclusions and recommendations have been rephrased and added to throughout the current document.

Changed or new conclusions and recommendations can be found in sections:

5.9 Guidelines for the Diagnosis and staging of testicular cancer

Biopsy of the contralateral testis should be offered (and its consequences discussed) to patients at high risk for contralateral TIN.	A
---	---

TIN = testicular intraepithelial neoplasia.

7.3.6 Guidelines for the treatment of NSGCT stage I

CS1B (pT2-pT4): high risk	LE	GR
Primary chemotherapy with one course of BEP is recommended	2a	A*
Patients should be informed about the advantages and disadvantages of two courses of BEP.		

BEP = cisplatin, etoposide, and bleomycin.

Table 8.1: Recommended minimum follow-up schedule in a surveillance policy: stage I non-seminoma

Procedure	Year			
	1	2	3	4-5
Physical examination	4 times	4 times	4 times	Once/year
Tumour markers	4 times	4 times	4 times	Once/year
Plain radiography chest	Twice		Twice	
Abdominopelvic CT	Twice (at 3 and 12 months)		Once in year 2 (at 24 months), Once in year 3 (at 36 months)	

CT = computed tomography.

Table 8.2: Recommended minimum follow-up schedule after retroperitoneal lymphadenectomy or adjuvant chemotherapy: stage I non-seminoma

Procedure	Year				
	1	2	3	4-5	6-10
Physical examination	4 times	4 times	4 times	Once/year	Once/year
Tumour markers	4 times	4 times	4 times	Once/year	Once/year
Plain radiography chest	Twice	Twice	Twice		
Abdominopelvic CT	Once	Once	Once	Once/year	

CT = computed tomography.

Table 8.3: Recommended minimum follow-up schedule for post-orchietomy surveillance, radiotherapy or chemotherapy: stage I seminoma

Procedure	Year		
	1	2	3-5
Physical examination	3 times	3 times	Once/year
Tumour markers	3 times	3 times	Once/year
Plain radiography chest	Twice	Twice	
Abdominopelvic CT	Twice	Twice	at 36 and 60 months

CT = computed tomography.

Table 8.4: Recommended minimum follow-up schedule in metastatic NSGCT and seminoma

Procedure	Year			
	1	2	3-5	Thereafter
Physical examination	4 times	4 times	Twice/year	Once/year
Tumour markers	4 times	4 times	Twice/year	Once/year
Plain radiography chest	4 times	4 times	Twice/year	Once/year
Abdominopelvic CT*†	Twice	Twice	Once/year	As indicated
Chest CT†‡	Once/year	Once/year	Once/year	As indicated
Brain CT§	Once/year	Once/year	Once/year	As indicated

CT = computed tomography.

* An abdominal CT must be performed at least annually if teratoma is found in the retroperitoneum.

† If the post-chemotherapy evaluation in a seminoma patient shows any mass > 3 cm, the appropriate CT should be repeated 2 and 4 months later to ensure that the mass is continuing to regress. If available, FDG-PET/CT can be performed.

‡ A chest CT is indicated if abnormality is detected on a plain radiography chest and after pulmonary resection.

§ In patients with headaches, focal neurological findings, or any central nervous system symptoms.

2. METHODS

For the Germ-cell tumour Section, the literature has been assessed and updated throughout the document.

For the Testicular Stromal tumours a scoping search as of Jan 1st, 2009 until October 13th, 2014 has been carried out. No restrictions on data level were applied. The search identified 758 unique records, of which 18 references were included in the manuscript.

2.1 Review

This document was subjected to double-blind peer review prior to publication.

3. EPIDEMIOLOGY, AETIOLOGY AND PATHOLOGY

3.1 Epidemiology

Testicular cancer represents 1% of male neoplasms and 5% of urological tumours, with 3-10 new cases occurring per 100,000 males/per year in Western society [2-5]. Its incidence has been increasing during the last decades especially in the industrialised countries [6-8]. Data from the Surveillance Epidemiology and End Results (SEER) program (1973 to 1998) show a continuing increased risk among Caucasian men in the USA only for seminoma [9].

At diagnosis, 1-2% of cases are bilateral and the predominant histology is germ cell tumour (90-95% of cases) [2]. Peak incidence is in the third decade of life for non-seminoma, and in the fourth decade for pure seminoma.

Testicular cancers (TC) show excellent cure rates based on their chemosensitivity especially to cisplatin-based chemotherapy [10], careful staging at diagnosis, adequate early treatment based on multidisciplinary approach and strict follow-up and salvage therapies. A decrease in the mean time of delay to diagnosis and treatment has been observed. Although early stages can be successfully treated in a non-reference centre, the relapse rate is higher [11]. In poor prognosis non-seminomatous germ cell tumours, overall survival (OS) within a clinical trial depends on the number of patients treated at the participating centre (worse if < 5 patients enrolled) [12]. In the same context, the frequency of post-chemotherapy residual tumour resection is associated with perioperative mortality and OS [13, 14].

Genetic changes have been described in patients with testicular cancer. A specific genetic marker (an isochromosome of the short arm of chromosome 12 - i(12p) - has been described in all histological types of germ cell tumours [15] and in testicular intraepithelial neoplasia (TIN). Alterations in the p53 locus have been identified in 66% of cases of testicular TIN [16]. A deregulation in the pluripotent program of foetal germ cells (identified by specific markers, M2A, C-KIT and OCT4/NANOG) is likely responsible for the development of TIN and germ cell neoplasia. There is overlap in the development to seminoma and embryonal carcinoma as shown by genome-wide expression analysis and detection of alpha-fetoprotein (AFP) mRNA in some atypical seminoma [17, 18].

Epidemiological risk factors for the development of testicular tumours are components of the testicular dysgenesis syndrome (i.e. cryptorchidism, hypospadias, decreased spermatogenesis evidenced by sub- or infertility) [19, 20], familial history of testicular tumours among first-grade relatives and the presence of a contralateral tumour or TIN [15, 19, 21-29]. Very tall men seem to have a higher risk of GCT (OR 3.35), while short stature is protective [30, 31], although further confirmation is needed.

3.2 Pathological classification

The recommended pathological classification (modified from the 2004 version of the World Health Organization [WHO] guidance) is shown below [32].

1. Germ cell tumours

- Intratubular germ cell neoplasia, unclassified type (IGCNU)
- Seminoma (including cases with syncytiotrophoblastic cells)
- Spermatocytic seminoma (mention if there is a sarcomatous component)
- Embryonal carcinoma

- Yolk sac tumour
- Choriocarcinoma
- Teratoma (mature, immature, with malignant component)
- Tumours with more than one histological type (specify percentage of individual components).

2. **Sex cord/gonadal stromal tumours**

- Leydig cell tumour
- Malignant Leydig cell tumour
- Sertoli cell tumour
 - lipid-rich variant
 - sclerosing
 - large cell calcifying
- Malignant Sertoli cell tumour
- Granulosa cell tumour
 - adult type
 - juvenile type
- Thecoma/fibroma group of tumours
- Other sex cord/gonadal stromal tumours
 - incompletely differentiated
 - mixed
- Tumours containing germ cell and sex cord/gonadal stromal (gonadoblastoma).

3. **Miscellaneous non-specific stromal tumours**

- Ovarian epithelial tumours
- Tumours of the collecting ducts and rete testis
- Tumours (benign and malignant) of non-specific stroma.

4. **STAGING AND CLASSIFICATION SYSTEMS**

4.1 **Diagnostic tools**

To determine the presence of macroscopic or occult metastatic disease, the half-life kinetics of serum tumour markers as well as the presence of nodal or visceral metastases need to be assessed.

Consequently, it is mandatory to assess:

- the post-orchietomy half-life kinetics of serum tumour markers;
- the status of retroperitoneal and supraclavicular lymph nodes, bone and liver;
- the presence or absence of mediastinal nodal involvement and lung metastases;
- the status of brain and bone in cases of suspicious symptoms or high-risk disease, e.g. poor IGCCCG risk group, high hCG and/or multiple pulmonary metastases.

The minimum mandatory tests are:

- serial blood sampling;
- abdominopelvic and chest computed tomography (CT).

4.2 **Serum tumour markers: post-orchietomy half-life kinetics**

The mean serum half-life of AFP and hCG is 5-7 days and 2-3 days, respectively [33]. Tumour markers need to be re-evaluated after orchietomy to determine half-life kinetics. Marker decline in patients with clinical stage I disease should be assessed until normalisation has occurred. Markers before the start of chemotherapy are important to classify the patient according to the International Germ Cell Cancer Collaborative Group (IGCCCG) risk classification [34]. The persistence of elevated serum tumour markers after orchietomy might indicate the presence of metastatic disease (macro- or microscopically), while the normalisation of marker levels after orchietomy does not rule out the presence of tumour metastases. During chemotherapy, the markers should decline; persistence has an adverse prognostic value [35, 36]. Slow marker decline in patients with “poor prognosis” during the first cycle of standard BEP chemotherapy can be used as an indication for early chemotherapy dose intensification [37].

4.3 **Retroperitoneal, mediastinal and supraclavicular lymph nodes and viscera**

Retroperitoneal and mediastinal lymph nodes are best assessed by CT. The supraclavicular nodes are best assessed by physical examination.

Abdominopelvic CT offers a sensitivity of 70-80% in determining the state of the retroperitoneal nodes. Its accuracy depends on the size and shape of the nodes; sensitivity and the negative predictive value increase using a 3 mm threshold to define metastatic nodes in the landing zones [38]. Those figures decrease slightly in stages I and II [39, 40], with a rate of understaging of 25-30% [41]. New generations of CT devices do not seem to improve the sensitivity.

Magnetic resonance imaging (MRI) produces similar results to CT in the detection of retroperitoneal nodal enlargement [42, 43]. Again, the main objections to its routine use are its high cost and limited availability. Nevertheless, MRI can be helpful when abdominopelvic CT or US are inconclusive [42], when CT is contraindicated because of allergy to contrast media, or when the physician or the patient are concerned about radiation dose. MRI is an optional test, and there are currently no indications for its systematic use in the staging of testicular cancer.

A chest CT is the most sensitive way to evaluate the thorax and mediastinal nodes. This exploration has to be recommended in all patients with testicular cancer as up to 10% of cases can present with small subpleural nodes that are not visible radiologically [44]. A CT has high sensitivity, but low specificity [42].

There is no evidence to support the use of fluorodeoxyglucose-PET (FDG-PET) in the staging of testis cancer [45-48]. It is recommended in the follow-up of patients with seminoma with any residual mass at least 6 weeks after the end of the last cycle of chemotherapy in order to decide on watchful waiting or active treatment [47-51].

Fluorodeoxyglucose-PET, however, is not recommended in the re-staging of patients with non-seminomatous tumours after chemotherapy [52, 53].

Other examinations, such as brain or spinal CT, bone scan or liver ultrasound, should be performed if there is suspicion of metastases to these organs. A CT or MRI of the skull is advisable in patients with NSGCT and multiple lung metastases and poor prognosis IGCCG risk group (e.g. high beta-hCG values). Table 4.1 shows the recommended tests at staging.

Table 4.1: Recommended tests for staging at diagnosis

Test	Recommendation	GR
Serum tumour markers	Alpha-fetoprotein hCG LDH	A
Abdominopelvic CT	All patients	A
Chest CT	All patients	A
Testis ultrasound (bilateral)	All patients	A
Bone scan or MRI columna	In case of symptoms	
Brain scan (CT/MRI)	In case of symptoms and patients with metastatic disease with multiple lung metastases and/or high beta-hCG values.	
Further investigations		
Fertility investigations: Total testosterone LH FSH Semen analysis		B
Sperm banking	Should be offered	A

hCG = human chorionic gonadotrophin; LDH = lactate dehydrogenase; CT = computed tomography; LH = luteinising hormone; FSH = follicle-stimulating hormone.

4.4 Staging and prognostic classifications

The staging system recommended in these guidelines is the 2009 TNM of the International Union Against Cancer (UICC) (Table 4.2) [54]. This includes:

- determination of the anatomical extent of disease;
- assessment of serum tumour markers, including nadir values of hCG, AFP and LDH after orchiectomy (S category);
- definition of regional nodes;
- N-category modifications related to node size.

Table 4.2: TNM classification for testicular cancer (UICC, 2009, 7th edn. [54])

pT Primary tumour¹			
pTX	Primary tumour cannot be assessed (see note 1)		
pT0	No evidence of primary tumour (e.g. histological scar in testis)		
pTis	Intratubular germ cell neoplasia (testicular intraepithelial neoplasia)		
pT1	Tumour limited to testis and epididymis without vascular/lymphatic invasion: tumour may invade tunica albuginea but not tunica vaginalis		
pT2	Tumour limited to testis and epididymis with vascular/lymphatic invasion, or tumour extending through tunica albuginea with involvement of tunica vaginalis		
pT3	Tumour invades spermatic cord with or without vascular/lymphatic invasion		
pT4	Tumour invades scrotum with or without vascular/lymphatic invasion		
N Regional lymph nodes clinical			
NX	Regional lymph nodes cannot be assessed		
N0	No regional lymph node metastasis		
N1	Metastasis with a lymph node mass 2 cm or less in greatest dimension or multiple lymph nodes, none more than 2 cm in greatest dimension		
N2	Metastasis with a lymph node mass more than 2 cm but not more than 5 cm in greatest dimension, or multiple lymph nodes, any one mass more than 2 cm but not more than 5 cm in greatest dimension		
N3	Metastasis with a lymph node mass more than 5 cm in greatest dimension		
pN Pathological			
pNX	Regional lymph nodes cannot be assessed		
pN0	No regional lymph node metastasis		
pN1	Metastasis with a lymph node mass 2 cm or less in greatest dimension and 5 or fewer positive nodes, none more than 2 cm in greatest dimension		
pN2	Metastasis with a lymph node mass more than 2 cm but not more than 5 cm in greatest dimension; or more than 5 nodes positive, none more than 5 cm; or evidence of extranodal extension of tumour		
pN3	Metastasis with a lymph node mass more than 5 cm in greatest dimension		
M Distant metastasis			
MX	Distant metastasis cannot be assessed		
M0	No distant metastasis		
M1	Distant metastasis M1a Non-regional lymph node(s) or lung M1b Other sites		
S Serum tumour markers			
SX	Serum marker studies not available or not performed		
S0	Serum marker study levels within normal limits		
	LDH (U/l)	hCG (mIU/mL)	AFP (ng/mL)
S1	< 1.5 x N and	< 5,000 and	< 1,000
S2	1.5-10 x N or	5,000-50,000 or	1,000-10,000
S3	> 10 x N or	> 50,000 or	> 10,000

N indicates the upper limit of normal for the LDH assay.

LDH = lactate dehydrogenase; hCG = human chorionic gonadotrophin; AFP = alpha-fetoprotein.

¹Except for pTis and pT4, where radical orchidectomy is not always necessary for classification purposes, the extent of the primary tumour is classified after radical orchidectomy; see pT. In other circumstances, TX is used if no radical orchidectomy has been performed.

According to the 2009 TNM classification, stage I testicular cancer includes the following substages:

Stage grouping

Stage 0	pTis	N0	M0	S0,SX
Stage I	pT1-T4	N0	M0	SX
Stage IA	pT1	N0	M0	S0
Stage IB	pT2 - pT4	N0	M0	S0
Stage IS	Any patient/TX	N0	M0	S1-3
Stage II	Any patient/TX	N1-N3	M0	SX
Stage IIA	Any patient/TX	N1	M0	S0
	Any patient/TX	N1	M0	S1
Stage IIB	Any patient/TX	N2	M0	S0
	Any patient/TX	N2	M0	S1
Stage IIC	Any patient/TX	N3	M0	S0
	Any patient/TX	N3	M0	S1
Stage III	Any patient/TX	Any N	M1a	SX
Stage IIIA	Any patient/TX	Any N	M1a	S0
	Any patient/TX	Any N	M1a	S1
Stage IIIB	Any patient/TX	N1-N3	M0	S2
	Any patient/TX	Any N	M1a	S2
Stage IIIC	Any patient/TX	N1-N3	M0	S3
	Any patient/TX	Any N	M1a	S3
	Any patient/TX	Any N	M1b	Any S

- Stage IA patients have primary tumours limited to the testis and epididymis, with no evidence of microscopic vascular or lymphatic invasion by tumour cells on microscopy, no sign of metastases on clinical examination or imaging, and post-orchietomy serum tumour marker levels within normal limits. Marker decline in patients with clinical stage I disease should be assessed until normalisation.
- Stage IB patients have a more locally invasive primary tumour, but no sign of metastatic disease.
- Stage IS patients have persistently elevated (and usually increasing) serum tumour marker levels after orchietomy, indicating subclinical metastatic disease (or possibly a second germ cell tumour in the remaining testis).

In large population-based patient series, 75-80% of seminoma patients, and about 55% of patients with NSGCT cancer have stage I disease at diagnosis [55-57]. True stage IS (persistently elevated or increasing serum marker levels after orchietomy) is found in about 5% of non-seminoma patients.

In 1997, the IGCCCG defined a prognostic factor-based staging system for metastatic testis tumour based on identification of some clinical independent adverse factors. This staging system has been incorporated into the TNM Classification and uses histology, location of the primary tumour, location of metastases and prechemotherapy marker levels in serum as prognostic factors to categorise patients into 'good', 'intermediate' or 'poor' prognosis (Table 4.3) [34].

Table 4.3: Prognostic-based staging system for metastatic germ cell cancer (International Germ Cell Cancer Collaborative Group)*

Good-prognosis group	
<p><i>Non-seminoma (56% of cases)</i> 5-year PFS 89% 5-year survival 92%</p>	<p><i>All of the following criteria:</i></p> <ul style="list-style-type: none"> • Testis/retroperitoneal primary • No non-pulmonary visceral metastases • AFP < 1,000 ng/mL • hCG < 5,000 IU/L (1,000 ng/mL) • LDH < 1.5 x ULN
<p><i>Seminoma (90% of cases)</i> 5-year PFS 82% 5-year survival 86%</p>	<p><i>All of the following criteria:</i></p> <ul style="list-style-type: none"> • Any primary site • No non-pulmonary visceral metastases • Normal AFP • Any hCG • Any LDH
Intermediate prognosis group	
<p><i>Non-seminoma (28% of cases)</i> 5-year PFS 75% 5-year survival 80%</p>	<p><i>All of the following criteria:</i></p> <ul style="list-style-type: none"> • Testis/retroperitoneal primary • No non-pulmonary visceral metastases • AFP 1,000 - 10,000 ng/mL or • hCG 5,000 - 50,000 IU/L or • LDH 1.5 - 10 x ULN
<p><i>Seminoma (10% of cases)</i> 5-year PFS 67% 5-year survival 72%</p>	<p><i>All of the following criteria:</i></p> <ul style="list-style-type: none"> • Any primary site • Non-pulmonary visceral metastases • Normal AFP • Any hCG • Any LDH
Poor prognosis group	
<p><i>Non-seminoma (16% of cases)</i> 5-year PFS 41% 5-year survival 48%</p>	<p><i>Any of the following criteria:</i></p> <ul style="list-style-type: none"> • Mediastinal primary • Non-pulmonary visceral metastases • AFP > 10,000 ng/mL or • hCG > 50,000 IU/L (10,000 ng/mL) or • LDH > 10 x ULN
<p><i>Seminoma</i></p>	<p>No patients classified as poor prognosis</p>

*Pre-chemotherapy serum tumour markers should be assessed immediately prior to the administration of chemotherapy (same day).

PFS = progression-free survival; AFP = alpha-fetoprotein; hCG = human chorionic gonadotrophin; LDH = lactate dehydrogenase.

5. DIAGNOSTIC EVALUATION

5.1 Clinical examination

TC presents as a painless, unilateral testicular scrotal mass, as a casual US finding or revealed by a scrotal trauma [58]. Scrotal pain may be the first symptom in 20% of cases and it is present in up to 27% of patients with testicular cancer [58, 59]. Gynaecomastia appears in 7% of cases (more common in non-seminomatous tumours). Back and flank pain due to metastasis is present in about 11% of cases [59].

Diagnosis is delayed in around 10% of cases of testicular tumour that mimic orchioepididymitis [59], physical examination reveals the features of the mass and must always be carried out together with a general examination to find possible (supraclavicular) distant metastases, a palpable abdominal mass or gynaecomastia. Ultrasound (US) must be performed in any doubtful case. A correct diagnosis must be established in all patients with an intrascrotal mass [60].

5.2 Imaging of the testis

Currently, US serves to confirm the presence of a testicular mass and to explore the contralateral testis. Its sensitivity is almost 100%, and it has an important role in determining whether a mass is intra- or extratesticular [61]. Ultrasound is an inexpensive test and should be performed even in the presence of clinically evident testicular tumour [62].

US of the testis should be performed in young men with retroperitoneal or visceral masses and/or elevated serum human chorionic gonadotrophin (hCG) or alpha-fetoprotein (AFP) and/or consulting for fertility problems and without a palpable testicular mass [63-65].

Magnetic resonance imaging (MRI) of scrotum offers higher sensitivity and specificity than US in the diagnosis of TC, but its high cost does not justify its routine use for diagnosis [61, 66].

5.3 Serum tumour markers at diagnosis

Serum tumour markers are prognostic factors and contribute to diagnosis and staging [67]. The following markers should be determined before, and 5-7 days after, orchiectomy:

- AFP (produced by yolk sac cells);
- hCG (expression of trophoblasts);
- LDH (lactate dehydrogenase).

Tumour markers are of value for diagnosis (before orchiectomy) as well as for prognosis (after orchiectomy). They are increased in approximately every second patient with testicular cancer [5, 58]. AFP and hCG are increased in 50-70% and in 40-60% of patients with non-seminomatous germ cell tumour (NSGCT), respectively. About 90% of NSGCT present with a rise in one or two of the markers. Up to 30% of seminomas can present or develop an elevated hCG level during the course of the disease [33, 68].

LDH is a less specific marker, its concentration being proportional to tumour volume. Its level may be elevated in 80% of patients with advanced testicular cancer [33]. Of note, negative marker levels do not exclude the diagnosis of a germ cell tumour. Placental alkaline phosphatase (PLAP), is an optional marker in monitoring patients with pure seminoma, but not recommended in smokers [69].

Cytogenetic and molecular markers are available in specific centres, but at present only contribute to research.

5.4 Inguinal exploration and orchiectomy

Every patient with a suspected testicular mass must undergo inguinal exploration with exteriorisation of the testis within its tunics. Orchiectomy with division of the spermatic cord at the internal inguinal ring must be performed if a malignant tumour is found. If the diagnosis is not clear, a testicular biopsy (and enucleation of the intraparenchymal tumour) is taken for frozen (fresh tissue) section histological examination.

In cases of life threatening disseminated disease, lifesaving chemotherapy should be given up-front, especially when the clinical picture is very likely testicular cancer and/or tumour markers are increased. Orchiectomy may be delayed until clinical stabilisation occurs or in combination with resection of residual lesions.

5.5 Organ-sparing surgery

Although organ-sparing surgery is not indicated in the presence of non-tumoural contralateral testis, it can be attempted in special cases with all the necessary precautions.

In synchronous bilateral testicular tumours, metachronous contralateral tumours, or in a tumour in a solitary testis with normal pre-operative testosterone levels, organ preserving surgery can be performed when tumour volume is less than 30% of the testicular volume and surgical rules are respected. In those cases, the rate of associated TIN is high (at least up to 82%) (see Section 5.7.)

5.6 Pathological examination of the testis

Mandatory pathological requirements:

- Macroscopic features: side, testis size, maximum tumour size, and macroscopic features of the epididymis, spermatic cord, and tunica vaginalis.
- Sampling: a 1 cm² section for every centimetre of maximum tumour diameter, including normal macroscopic parenchyma (if present), albuginea and epididymis, with selection of suspected areas. At least one proximal and one distal section of spermatic cord plus any suspected area.
- Microscopic features and diagnosis: histological type (specify individual components and estimate amount as percentage) according to WHO 2004 [32]:
 - presence or absence of peri-tumoural venous and/or lymphatic invasion;
 - presence or absence of albuginea, tunica vaginalis, rete testis, epididymis or spermatic cord invasion;

- presence or absence of (TIN/ITGCN [intratubular germ cell neoplasia]) in non-tumour parenchyma
Intratubular germ cell neoplasia.
- pT category according to Tumour Node Metastasis (TNM) 2009 [54].
- Immunohistochemical studies: in seminoma and mixed germ cell tumour, AFP and hCG.

Advisable immunohistochemical markers, in cases of doubt, are:

- in seminoma: cytokeratins (CAM 5.2), PLAP, c-kit;
- in intratubular germ cell neoplasia: PLAP, c-kit;
- other advisable markers: chromogranin A (Cg A), Ki-67 (MIB-1).

5.7 Diagnosis and treatment of testicular intraepithelial neoplasia (TIN)

Contralateral biopsy has been advocated to rule out the presence of TIN [70]. Although routine policy in some countries, the low incidence of TIN and contralateral metachronous testicular tumours (up to 9% and approximately 2.5%, respectively) [71, 72], the morbidity of TIN treatment, and the fact that most of metachronous tumours are at a low stage at presentation make it controversial to recommend a systematic contralateral biopsy in all patients [73-75].

It is still difficult to reach a consensus on whether the existence of contralateral TIN must be identified in all cases. However, biopsy of the contralateral testis should be offered to patients at high risk for contralateral TIN, i.e. testicular volume < 12 mL, a history of cryptorchidism or poor spermatogenesis (Johnson Score 1-3). A contralateral biopsy is not necessary in patients older than 40 years without risk factors [38, 57, 76-79]. A double biopsy increases sensitivity [77]. Patients should be informed that a testicular tumour may arise in spite of a negative biopsy [80].

Once TIN is diagnosed, local radiotherapy (16-20 Gy in fractions of 2 Gy) is the treatment of choice in the case of a solitary testis. Testicular radiotherapy in a solitary testis will result in infertility and increased long-term risk of Leydig cell insufficiency [39, 73, 81, 82]. Fertile patients who wish to father children may delay radiation therapy and be followed by regular testicular US [77].

If TIN is diagnosed and the contralateral testis is healthy, the options for management are orchiectomy or close observation (with a 5-year risk of developing TC of 50%) [83].

5.8 Screening

There are no surveys proving the advantages of screening programmes, but it has been demonstrated that stage and prognosis are directly related to early diagnosis. In the presence of clinical risk factors, self-physical examination by the affected individual is advisable.

5.9 Guidelines for the diagnosis and staging of testicular cancer

	GR
Testicular US is a mandatory assessment.	A
Biopsy of the contralateral testis should be offered (and its consequences discussed) to patients at high risk for contralateral TIN.	A
Orchiectomy and pathological examination of the testis are necessary to confirm the diagnosis and to define the local extension (pT category). In a life-threatening situation due to extensive metastasis, chemotherapy must be started before orchiectomy.	A
Serum determination of tumour markers (AFP, hCG, and LDH) must be performed both before and 5-7 days after orchiectomy for staging and prognostic reasons.	A
The state of the retroperitoneal, mediastinal and supraclavicular nodes and viscera must be assessed in testicular cancer.	A

AFP = alpha-fetoprotein; hCG = human chorionic gonadotrophin; LDH = lactate dehydrogenase; TIN = testicular intraepithelial neoplasia.

6. PROGNOSIS

6.1 Risk factors for metastatic relapse in stage I GCT

Retrospectively, for seminoma stage I, tumour size (> 4 cm) and invasion of the rete testis have been identified as predictors for relapse in a pooled analysis [84]. However, these risk factors have not been validated in a prospective setting except that the absence of both factors indicated a low recurrence rate (6%) [85].

For non-seminoma stage I, vascular invasion of the primary tumour in blood or lymphatic vessels is the most important predictor of occult metastatic disease. The proliferation rate, as well as the percentage of embryonal carcinoma, are additional predictors that improve upon the positive and negative predictive value of vascular invasion [86, 87]. Whether the absence of teratoma (as qualitative data, as opposed to the more subjective assessment of percentage of embryonal carcinoma) can independently complement vascular invasion as a predictive factor of relapse requires validation [88].

The significant prognostic pathological risk factors for stage I testicular cancer are listed in Table 6.1.

Table 6.1: Risk factors for occult metastatic disease in stage I testicular cancer

	For seminoma	For non-seminoma
Pathological (for stage I)		
Histopathological type	<ul style="list-style-type: none">• Tumour size (> 4 cm)• Invasion of the rete testis	<ul style="list-style-type: none">• Vascular/lymphatic in or peri-tumoural invasion• Proliferation rate > 70%• Percentage of embryonal carcinoma > 50%

7. DISEASE MANAGEMENT

7.1 Impact on fertility and fertility-associated issues

Sperm abnormalities are frequently found in patients with testis tumours. Furthermore, chemotherapy and radiation treatment can also impair fertility. In patients in the reproductive age group, pre-treatment fertility assessment (testosterone, luteinising hormone [LH] and follicle stimulating hormone [FSH] levels) should be performed, and semen analysis and cryopreservation should be offered. If cryopreservation is desired, it should preferably be performed before orchiectomy, but in any case prior to chemotherapy treatment [81, 89-95]. In cases of bilateral orchiectomy or low testosterone levels after treatment of TIN, life-long testosterone supplementation is necessary [96]. Patients with unilateral or bilateral orchiectomy should be offered a testicular prosthesis [97]. For more detailed information, the reader is referred to the EAU Male Infertility Guidelines [98].

7.2 Stage I Germ cell tumours

7.2.1 Stage I seminoma

After modern staging procedures, about 15-20% of stage I seminoma patients have subclinical metastatic disease, usually in the retroperitoneum, and will relapse after orchiectomy alone.

The decision regarding adjuvant treatment should always be based on a thorough discussion with the patient, taking into account the described advantages and disadvantages, as well as the individual situation of the patient.

7.2.1.1 Surveillance

Several prospective non-randomised surveillance studies have been conducted during the past decade, the largest study from Canada with > 1,500 patients [99]. Previous analyses from four studies showed an actuarial 5-year relapse-free rate of 82.3%. The Princess Margaret Hospital series (n = 1559) showed an overall relapse rate in unselected patients of 16.8%. The actuarial relapse rate is in the order of 15-20% at 5 years, and most of the relapses are first detected in infra-diaphragmatic lymph nodes [100].

In patients with low risk (tumour size ≤ 4 cm and no rete testis invasion), the recurrence under surveillance is as low as 6% [101]. Chemotherapy, according to the IGCCCG classification, is a possible treatment for seminoma relapse under surveillance. However, 70% of patients with relapse are suitable for treatment with radiotherapy alone because of small volume disease at the time of recurrence. Patients who relapse after salvage radiotherapy can be effectively treated with chemotherapy [102]. The combination of

carboplatin chemotherapy and modern radiotherapy for treatment of low stage seminoma relapse (IIA/IIB) is under investigation.

The overall cancer-specific survival rate reported under surveillance performed by experienced centres is 97-100% for seminoma stage I [100, 102]. The main drawback of surveillance is the need for more intensive follow-up, especially with repeated imaging examinations of the retroperitoneal lymph nodes.

7.2.1.2 Adjuvant chemotherapy

A joint trial by the Medical Research Council (MRC) and the European Organisation for Research and Treatment of Cancer (EORTC) (MRC TE 19 trial), which compared one cycle of carboplatin (area under curve [AUC] 7) with adjuvant radiotherapy, did not show a significant difference with regard to recurrence rate, time to recurrence and survival after a median follow-up of 4 years [103-105]. Therefore, adjuvant carboplatin therapy using a dosage of one course of AUC 7 is an alternative to radiotherapy or surveillance in stage I seminoma [100, 103-105]. Two courses of adjuvant carboplatin seem to further reduce the relapse rate to the order of 1-3% [85, 106], but additional experience and long-term observation are needed.

7.2.1.3 Adjuvant radiotherapy and risk-adapted treatment

Seminoma cells are extremely radiosensitive. Adjuvant radiotherapy to a para-aortic (PA) field or to a paraaortic and ipsilateral field (para-aortic and ipsilateral iliac nodes), with moderate doses (total 20-24 Gy), will reduce the relapse rate to 1-3% [107-110]. Adjuvant irradiation of supradiaphragmatic lymph nodes is not indicated in seminoma stage I.

With regard to the irradiation dose, a large MRC randomised trial of 20 Gy versus 30 Gy PA radiation in stage I seminoma showed equivalence for both doses in terms of recurrence rates [108]. The rate of severe radiation-induced long-term toxicity is less than 2%. Moderate chronic gastrointestinal (GI) side-effects are seen in about 5% of patients, and moderate acute GI toxicity in about 60% [107]. The main concern surrounding adjuvant radiotherapy is the increased risk of radiation-induced second non-germ cell malignancies [111-116]. Therefore, in young patients (< 40 yrs) adjuvant radiotherapy should no longer be used.

A scrotal shield should be considered during adjuvant radiotherapy in order to prevent scattered radiation toxicity in the contralateral testis [114].

7.2.1.4 Risk-adapted treatment

Using tumour size > 4 cm and rete testis invasion, patients with seminoma stage I may be subdivided into a low- and high-risk group of occult metastatic disease. Patients with and without both risk factors have a risk of occult disease of 32% and 12%, respectively. These risk factors were introduced by an analysis of retrospective trials [84]. A prospective trial based on these risk factors (no risk factors: surveillance; both risk factors: two courses of carboplatin AUC 7) showed the feasibility of a risk-adapted approach. Early data with limited follow-up indicate that patients without either risk factor have a very low risk of 6.0% - 14.8% of relapse at 5 years. Patients in the high-risk group treated with carboplatin experienced a 1.4% - 3.2% relapse rate at mean follow up of 34 months [101, 117].

7.2.1.5 Retroperitoneal lymph node dissection (RPLND)

In a prospective, non-randomised study comparing radiotherapy and RPLND in stage I seminoma, there was a trend towards a higher incidence of retroperitoneal relapses (9.5%) after RPLND as primary treatment. Therefore, this policy should not be recommended in stage I seminoma [115].

7.2.2 Guidelines for the treatment of seminoma stage I

	GR
Surveillance is a recommended management option (if facilities available and patient compliant).	A*
Carboplatin-based chemotherapy (one course at AUC 7) is recommended.	B
Adjuvant treatment is not recommended for patients at very low risk.	A
Radiotherapy is not recommended as adjuvant treatment.	A

*Upgraded following panel consensus.

7.3 NSGCT clinical stage I

Up to 30% of NSGCT patients with clinical stage I (CS1) disease have subclinical metastases and will relapse if surveillance alone is applied after orchiectomy. The decision regarding adjuvant treatment should always be based on a thorough discussion with the patient, taking into account the described advantages and

disadvantages, as well as the individual situation of the patient.

7.3.1 **Surveillance**

Improvements in clinical staging and follow-up methods, and the availability of effective salvage treatment with cisplatin-based chemotherapy and post-chemotherapy surgery, have led to studies of only close surveillance after orchiectomy in CS1 NSGCT patients. The largest reports of the surveillance strategy indicate a cumulative relapse rate of about 30%, with 80% of relapses occurring during the first 12 months of follow-up, 12% during the second year and 6% during the third year, decreasing to 1% during the fourth and fifth years, and occasionally even later [118-122]. About 35% of relapsing patients have normal levels of serum tumour markers at relapse. About 60% of relapses are in the retroperitoneum. Despite very close follow-up, 11% of relapsing patients presented with large-volume recurrent disease.

The somewhat lower relapse rates reported from surveillance studies compared with some series of patients staged by RPLND [123] can be explained by the fact that some patients (presumably at higher risk) are excluded once surveillance is advised. Based on the overall cancer-specific survival data, surveillance within an experienced surveillance programme can safely be offered to patients with non-risk stratified clinical stage I non-seminoma as long as they are compliant and informed about the expected recurrence rate as well as the salvage treatment [124-126].

7.3.2 **Adjuvant chemotherapy**

Patients with CS1 NSGCT have a 14-48% risk of recurrence within 2 years after orchiectomy. Adjuvant chemotherapy with two courses of cisplatin, etoposide, and bleomycin (BEP) was introduced in 1996 by a prospective MRC trial [127]. Subsequently, adjuvant chemotherapy was mainly given in patients with high risk (vascular invasion present) [127-132]. In these series, involving more than 200 patients, some with a median follow-up of nearly 7.9 years [127], a relapse rate of only 2.7% was reported, with very little long-term toxicity. Two cycles of cisplatin-based adjuvant chemotherapy do not seem to adversely affect fertility or sexual activity [133]. However, the very-long term (> 20 years) side effects of adjuvant chemotherapy in this setting are currently unknown, especially the long-term cardio-vascular effects of chemotherapy [134]. This should be taken in consideration for decision-making.

In 2008, the German Testicular Study Group reported a randomised trial of nerve-sparing RPLND or one course of BEP as adjuvant treatment in CS 1 NSGCT without risk-adaption. Adjuvant chemotherapy significantly increased the 2-year recurrence-free survival to 99.41% (confidence interval (CI): 95.87%, 99.92%) as opposed to surgery, which had a 2-year recurrence-free survival of 92.37% (CI: 87.21%, 95.50%). The difference was 7.04%, CI: 2.52%, 11.56% and, therefore, the main endpoint of the trial was reached. The hazard ratio to experience a tumour recurrence with surgery as opposed to chemotherapy was 7.937, CI: 1.808, 34.48. Of 174 patients having received one course of BEP, 43% had high risk features (> pT1) [135].

In a community-based prospective study, SWENOTECA recommended one course of BEP in LVI+ patients, while patients with LVI- chose between surveillance and BEP x 1 [136]. The relapse-rate of the 490 patients who received BEP x 1 at 5 years was 3.2% for patients with LVI and 1.6% for patients without LVI. After a median follow-up of 8.1 years the relapse rate was 2.3%, 3.4% and 1.3% for all, LVI+, and LVI-, respectively [137]. These numbers imply that > 90% of relapses were prevented by adjuvant chemotherapy and, importantly, no relapses were observed later than 3.3 years. Reduction from two to one cycle of BEP improves the risk-benefit ratio of adjuvant chemotherapy considerably.

In addition, it is important to be aware of slow-growing retroperitoneal teratomas after primary chemotherapy [138]. Until now, only a limited number of patients with long-term follow-up and toxicity data are reported so far [139].

The results of cost analyses comparing surveillance, RPLND and primary chemotherapy show different results among the reported studies, possibly because of differences in intensity and costs related to follow-up procedures [140]. With a low frequency of follow-up CTs (a surveillance strategy which has been proven to be effective in non-seminoma CS1), the costs of follow-up can be considerably reduced [141].

7.3.3 **Risk-adapted treatment**

Risk-adapted treatment is an alternative to the strategy of surveillance for all patients with CS 1 NSGCT. Risk-adapted treatment is based on the risk factor, vascular invasion. Stratifying patients with CS1 NSGCT according to their presumed risk of relapse is a rational option, as several studies have reported similar survival rates and a final cure rate close to 100% with all available treatment options using the risk-stratifying approach [127-132, 136, 137, 142-145].

If the risk-adapted policy is applied, patients with vascular invasion are recommended to undergo adjuvant chemotherapy and patients with absent vascular invasion are recommended a surveillance strategy. In the past, two cycles of BEP have been recommended for adjuvant treatment. In view of the low rates of recurrence (2-3%) and equivalent cancer-specific survival rates including salvage strategies in large prospective trials with sufficient follow-up, one cycle of BEP is recommended as adjuvant chemotherapy in patients with vascular invasion.

In cases of relapse after BEP x 1, three courses of BEP are recommended. However, there is not a large body of evidence to support one specific salvage regimen.

7.3.4 **Retroperitoneal lymph node dissection**

In view of the high cancer-specific survival rates of surveillance with salvage treatment in cases of relapse and the low relapse rates if adjuvant chemotherapy is chosen, the role of primary diagnostic retroperitoneal lymph node dissection has diminished. The randomised phase III trial of the German Testicular Cancer Study group compared RPLND to BEP x 1 as adjuvant treatment to show a more than expected difference of 7% in favour of chemotherapy. One course of BEP showed a significantly lower recurrence rate as compared to surgery [135].

If RPLND is performed in a multicentre setting, a higher rate of “in-field” recurrences and a higher rate of complications was reported [135, 146]. Thus, nerve-sparing RPLND - if indicated - should be performed by an experienced surgeon in specialised centres.

About 18-30% of patients are found to have retroperitoneal lymph node metastases on RPLND, corresponding to pathological stage II (PS2) disease [146-149]. If no retroperitoneal metastases are found at RPLND (PS1), approximately 10% of the PS1 patients relapse at distant sites [87, 124, 149, 150]. If metastases are present and not treated with adjuvant chemotherapy, recurrence will be found in 31% in patients [149].

The presence of vascular invasion, predominant embryonal carcinoma, pT category as well as a high number of and extranodal extension in metastatic nodes may be associated with an increased risk of recurrence in PS2 cases without adjuvant chemotherapy. Nonetheless, the clinical significance of these further parameters remains poor and not advisable in clinical practice [149, 151].

The follow-up after RPLND is simpler and less costly than that carried out during post-orchietomy surveillance because of the reduced need for abdominal CT scans [152]. If there is an indication to perform a staging RPLND, a laparoscopic or robot-assisted RPLND is feasible in expert hands. This minimal-invasive approach cannot be recommended as the standard approach outside of a specialised laparoscopic centre [153, 154].

7.3.5 **Guidelines for the treatment of NSGCT stage I**

	LE	GR
Patients with CS 1 NSGCT should be informed about all adjuvant treatment options after orchietomy (surveillance, adjuvant chemotherapy, and RPLND) including treatment-specific recurrence rates as well as acute and long-term side effects.	2a	A*
Surveillance or risk-adapted treatment based on vascular invasion (see below) are recommended treatment options.	2a	A*
If patients are not willing to undergo the surveillance strategy, one course of BEP as adjuvant treatment has proven to be superior to RPLND in terms of recurrence rate in a community based study.	1b	A*
Salvage treatment of patients with recurrence during surveillance consists of three or four courses of BEP chemotherapy according to IGCCCG classification followed by post-chemotherapy retroperitoneal lymph node dissection if necessary.	2a	A

7.3.6 Risk-adapted treatment for CS1 based on vascular invasion

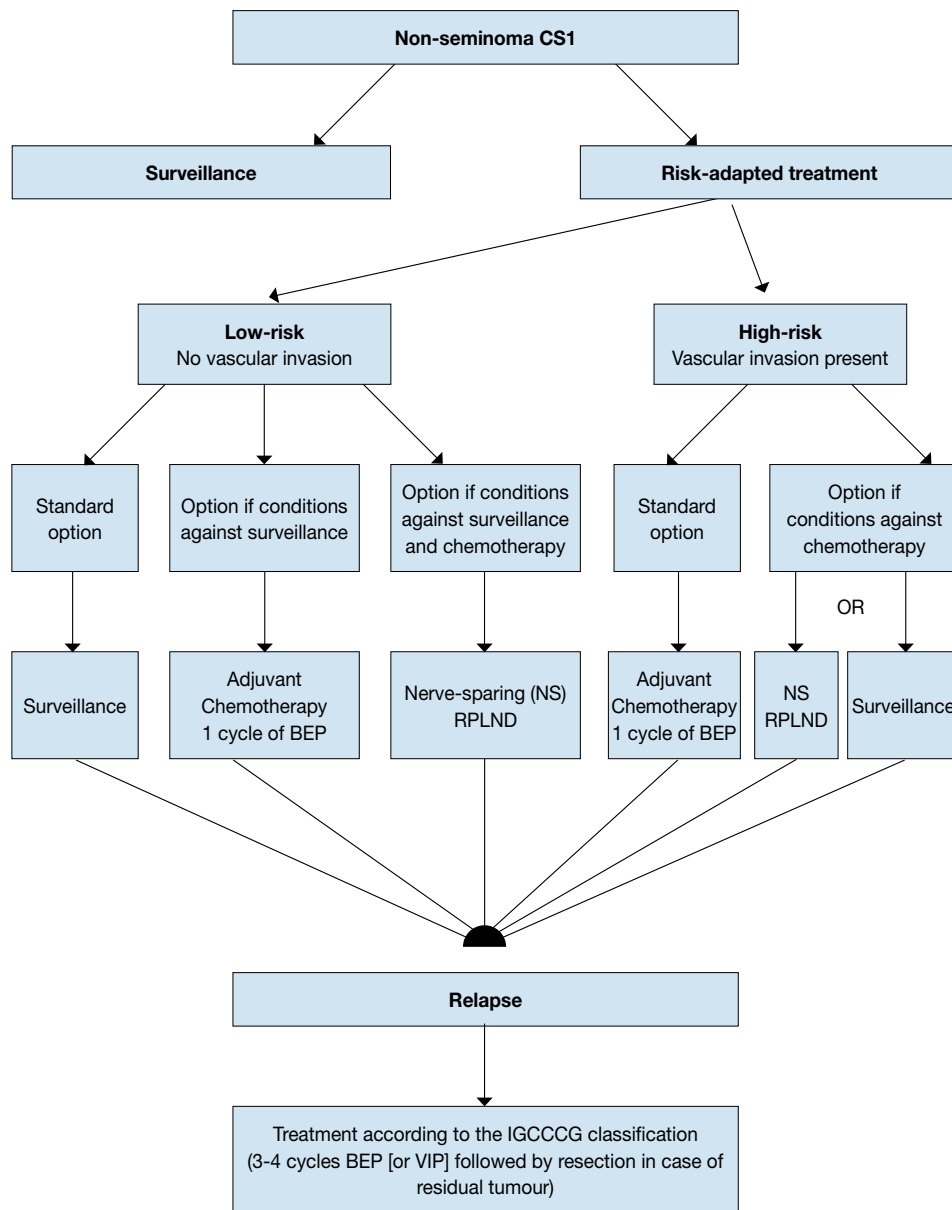
CS1A (pT1, no vascular invasion): low risk	LE	GR
Surveillance is recommended if the patient is willing and able to comply.	2a	A
In low-risk patients not willing (or suitable) to undergo surveillance, adjuvant chemotherapy with one course of BEP is recommended.	2a	A*
CS1B (pT2-pT4): high risk		
Primary chemotherapy with one course of BEP is recommended.	2a	A*
Patients should be informed about the advantages and disadvantages of two courses of BEP.		
Surveillance or nerve-sparing RPLND in high-risk patients remain options for those not willing to undergo adjuvant chemotherapy. If pathological stage II is revealed at RPLND, further chemotherapy as well as observation should be discussed with each patient.		A*

*Upgraded following panel consensus.

BEP = cisplatin, etoposide, bleomycin; RPLND = retroperitoneal lymph node dissection.

Figure 1 provides a treatment algorithm for patients with NSGCT stage I.

Figure 1: Risk-adapted treatment in patients with clinical stage 1 non-seminoma NSGCT CS1*



*All treatment options will need discussing with individual patients, to allow for them to make an informed decision as to their further care.

BEP = cisplatin, etoposide, bleomycin; CS = clinical stage; IGCCCG = International Germ Cell Cancer Collaborative Group; RLND = retroperitoneal lymph node dissection; VIP = etoposide, cisplatin, ifosfamide.

7.4 Metastatic germ cell tumours

The first-line treatment of metastatic germ cell tumours depends on:

- the histology of the primary tumour;
- prognostic groups as defined by the IGCCCG based on 5,202 non-seminoma and 660 seminoma cases (Table 4.3) [34].

In relapsed patients a new prognostic score has been developed including response to first-line therapy which can be used to estimate patient outcome following salvage chemotherapy.

7.4.1 **CS1S with (persistently) elevated serum tumour markers**

Serum tumour markers should be followed closely until levels fall into the reference values according to the expected half-life values for AFP and hCG. If the marker level increases after orchiectomy, the patient has residual disease. If RPLND is performed, up to 87% of these patients have pathologically documented nodes in the retroperitoneum [156]. An ultrasound examination of the contralateral testicle must be performed, if this was not done initially.

The treatment of true CS1S patients is still controversial. They may be treated with three courses of BEP chemotherapy and with follow-up as for CS1B patients (high risk, see below) after primary chemotherapy [157], or by RPLND [141].

7.4.2 **Metastatic disease (stage IIA/B)**

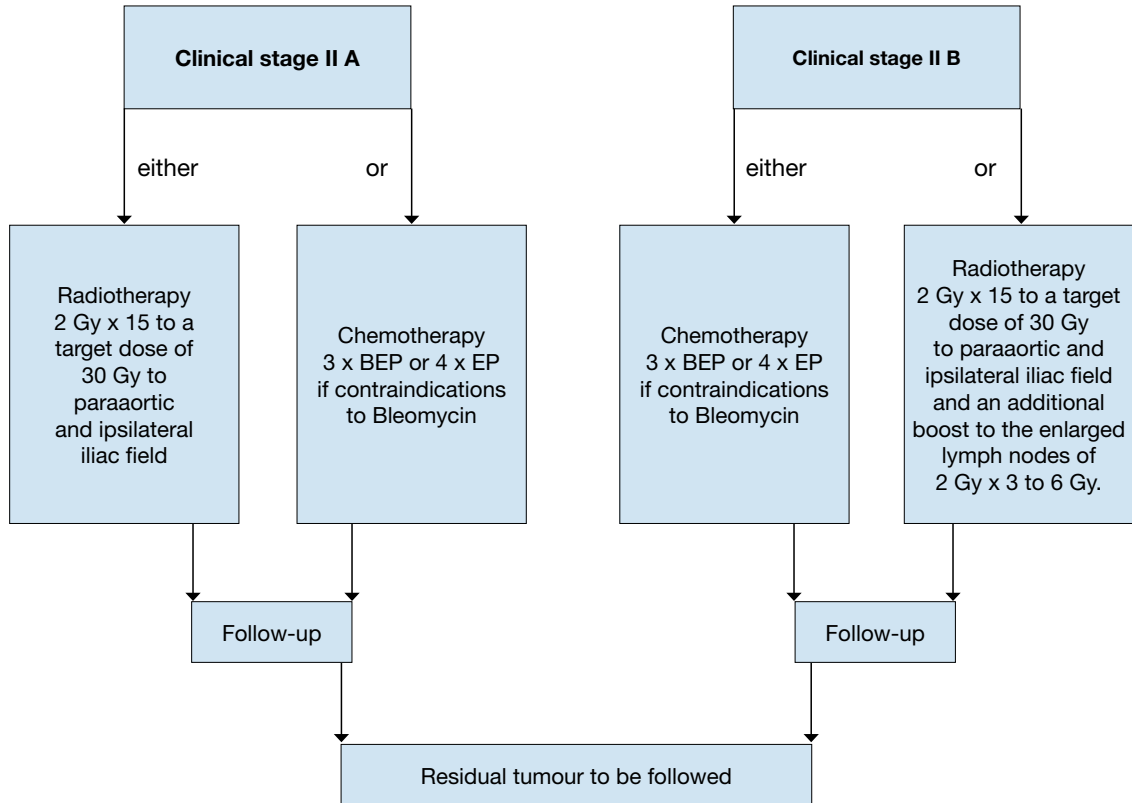
7.4.2.1 *Stage IIA/B seminoma*

Slightly enlarged retroperitoneal lymph nodes < 2 cm in patients without elevated tumour markers offer a diagnostic problem. These lymph nodes may be benign or, on the other hand, represent metastases. An observation period of 8 weeks with a second staging is recommended unless a biopsy verifies metastatic disease. Treatment should not be initiated unless metastatic disease is unequivocal, (e.g. growth or positive biopsy).

So far, the standard treatment for stage IIA/B seminoma has been radiotherapy with reported relapse rates of 9-24% [158-160]. Accumulating data on long-term morbidity, such as increased risk of cardiovascular events and increased risk of second malignancies following radiotherapy has led to concern. Most reports refer to patients irradiated with larger target volumes and higher doses but there are also more recent studies reporting on patients treated with more modern radiotherapy [56, 161]. The radiation dose delivered in stage IIA and IIB is approximately 30 Gy and 36 Gy, respectively. The standard radiation field compared with stage I will be extended from the PA region to the ipsilateral iliac field. In stage IIB, the lateral borders should include the metastatic lymph nodes with a safety margin of 1.0-1.5 cm. This technique yields a relapse-free survival in stage IIA and IIB of 92% and 90%, respectively. Overall survival is almost 100% [158, 159]. Conversely, dose reduction to 27 Gy has been associated with 11% of relapses [102, 161].

In stage IIA/B, chemotherapy; with 3 courses of BEP or 4 courses of etoposide and cisplatin (EP) in cases with contraindications to bleomycin is an alternative to radiotherapy. There are no randomised studies comparing radiotherapy versus chemotherapy. Although more toxic in the short term, 3 courses of BEP or 4 courses of EP achieve a similar level of disease control [162]. One population-based study with 67 stage IIB patients reported a relapse free-survival of 100% after a median of 5.5 years of follow-up [102]. Single-agent carboplatin is not an alternative to standard EP or BEP chemotherapy for metastatic disease [163].

Figure 2: Treatment options in patients with seminoma clinical stage II A and B



BEP = cisplatin, etoposide, bleomycin; EP = etoposide, cisplatin.

7.4.2.2 Stage IIA/B non-seminoma

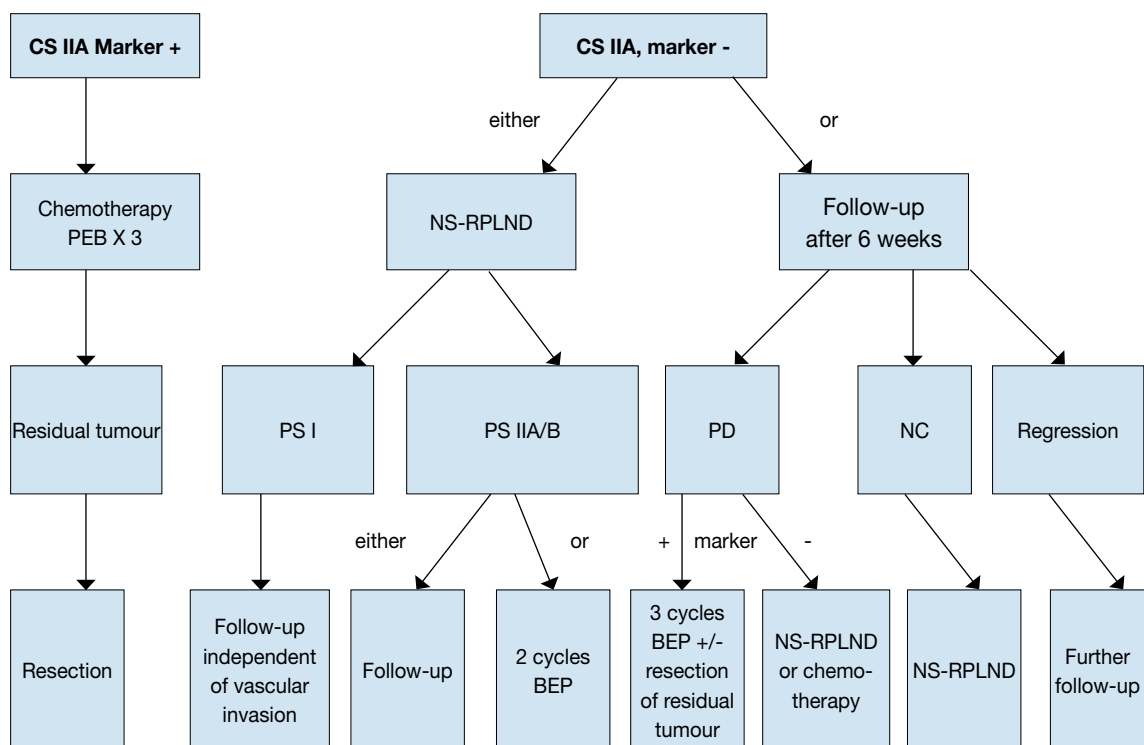
There is a general consensus that treatment should start with initial chemotherapy in all advanced cases of NSGCT except for stage II NSGCT disease without elevated tumour markers, which alternatively can be managed by primary RPLND or surveillance to clarify stage [140, 164, 165].

If surveillance is chosen, one follow-up evaluation after 6 weeks is indicated to document whether the lesion is growing, remaining stable or shrinking. A shrinking lesion is probably non-malignant in origin and should be observed further. A stable or growing lesion indicates either teratoma or an undifferentiated malignant tumour. If the lesion is growing without a corresponding increase in the tumour markers AFP or beta-hCG, RPLND represents the first option to be performed by an experienced surgeon because of suspected viable disease or teratoma [164]. Patients with a growing lesion and a concomitant increase in the tumour markers AFP or beta-hCG require primary chemotherapy with BEP according to the treatment algorithm for patients with metastatic disease and IGCCCG recommendations [166-168] (Figure 2). An alternative to the surveillance strategy in marker-negative II A/B non-seminoma with suspicion of an undifferentiated malignant tumour is a (CT-guided) biopsy, if technically possible. There is insufficient published data on PET scans in this situation.

When primary chemotherapy is refused by the patient or when it has some contraindications, primary nerve-sparing RPLND represents a viable option.

Primary chemotherapy and primary RPLND are comparable options in terms of outcome, but side-effects and toxicity are different, allowing for involvement of the patient in selecting the treatment of choice [169]. The cure rate with either approach will be close to 98% [170-176].

Figure 3: Treatment options in patients with non-seminoma clinical stage IIA



BEP = cisplatin, etoposide, bleomycin; NS = nerve-sparing; RPLND = retroperitoneal lymph node dissection; PS = pathological stage; PD = progressive disease; NC = no change.

7.4.3 Metastatic disease (stage IIC and III)

7.4.3.1 Primary chemotherapy

7.4.3.1.1 Good prognosis risk group - SGCT

For metastatic seminoma, only very limited data are available from randomised trials and they indicate that a cisplatin-based regimen should be preferred to carboplatin chemotherapy [177]. Recent data indicate that EP x 4 result in cure in almost all cases of good-prognosis seminomatous germ cell cancers [178]. Standard treatment in good-prognosis seminoma should therefore be 3 x BEP or 4 x EP. In the case of contraindications to Bleomycin, EP x 4 should be given [179]. Post-chemotherapy masses should be managed as described in Section 7.4.4.1.

7.4.3.1.2 Intermediate prognosis risk group - SGCT

For patients with intermediate-risk seminoma, 4 cycles of BEP or etoposide, cisplatin, ifosfamide (VIP) (in the case of contraindications to bleomycin) are recommended options, although no randomized trial has focused specifically on this group of rare patients [180].

7.4.3.1.3 Good prognosis risk group - NSGCT

For non-seminoma, the primary treatment of choice for metastatic disease in patients with good risk disease according to the IGCCCG risk classification is three cycles of BEP combination chemotherapy (Table 7.1). This regimen has proven superior to cisplatin, vinblastine and bleomycin (PVB) in patients with advanced disease [181-183]. While data support a 3-day regimen of administering combination chemotherapy to be equally effective as a 5-day regimen, this is associated with increased toxicity when four cycles are used [184], thus the 5-day BEP regimen is recommended.

Table 7.1: BEP regimen (interval 21 days)

Drug	Dosage	Duration of cycles
Cisplatin	20 mg/m ²	Days 1-5*
Etoposide	100 mg/m ²	Days 1-5
Bleomycin	30 mg	Days 1, 8, 15

*Plus hydration.

BEP = cisplatin, etoposide, bleomycin.

In selected cases where bleomycin is contraindicated, four cycles of EP can be given [34, 183, 185-187]. A randomised trial from the French Groupe d'Etude des Tumeurs Genito-Urinaires (GETUG) suggested that when the BEP is used in this setting the mortality was half that of EP, although the difference did not reach statistical significance [187, 188].

Therapy should be given without reduction of the doses at 21-day intervals; delaying the following chemotherapy cycle is justified only in cases of fever with granulocytopenia < 1000/mm³ or thrombocytopenia < 100,000/IU. There is no indication for prophylactic application of haematopoietic growth factors such as, for example, granulocyte colony-stimulating factor (G-CSF). However, if infectious complications have occurred during chemotherapy or the treatment interval was delayed due to myelotoxicity, prophylactic administration of G-CSF is recommended for the following cycles [185, 189].

7.4.3.1.4 Intermediate prognosis risk group - NSGCT

The 'intermediate prognosis' group in the IGCCCG has been defined as patients with a 5-year survival rate of about 80%. The available data support four cycles of BEP as standard treatment [34, 190]. A randomised trial has compared 4 cycles of BEP to 4 x BEP with the addition of paclitaxel (T-BEP) and did not show a significant improvement in OS [191]. The overall toxicity with T-BEP was higher than with BEP and thus it cannot be recommended as a standard approach.

7.4.3.1.5 Poor prognosis risk group - NSGCT

For patients with a 'poor prognosis' non-seminoma as defined by the IGCCCG and favourable marker decline, standard treatment consists of four cycles of BEP. Four cycles of cisplatin, etoposide and ifosfamide (PEI) have the same effect, but are more myelotoxic [192, 193]. The 5-year progression-free survival is between 45% and 50%. Three randomised trials have shown no advantage in OS for high-dose chemotherapy for the overall group of 'poor prognosis' patients [194-196].

However, patients with a slow tumour marker decline after the first or second cycle represent a prognostically inferior subgroup [36, 194].

An online calculator is available for free at www.igr.fr/calculatation-tumor/NSGCT.xls. Recently, an international randomised phase III trial (GETUG 13) conducted in 263 patients with IGCCCG poor-risk NSGCT demonstrated that intensifying treatment with dose-dense chemotherapy improves PFS, but not OS in patients with an early unfavourable tumour marker decline [37]. Based on the results from this trial, patients with an unfavourable tumour marker decline after one cycle of BEP should be switched to a more intensive chemotherapy regimen [197]. Further prospective trials /registries are planned to validate this approach further.

Since a matched-pair analysis comparing high-dose to conventional treatment resulted in a better survival rate [36, 198, 199], poor prognosis patients should still be treated in ongoing prospective trials or registries, whenever available.

Patients meeting 'poor-prognosis' criteria should be transferred to a reference centre as a better outcome was reported for intermediate and poor prognosis patients who had been treated within a clinical trial in a high volume centre [12, 200]. There are no general recommendations for treatment modifications for patients with a poor general condition (Karnofsky < 50%) or extended liver infiltration (> 50%), but two small reports indicate that a first cycle of dose reduced therapy may reduce acute mortality without compromising long-term outcome, however, the number of subsequent cycles of full dose therapy should not be reduced after a first low dose induction cycle [201, 202].

Patients with extended pulmonary infiltration are at risk for acute respiratory distress syndrome: adapting the doses of the BEP regimen in the first cycle of chemotherapy (only 3 days of EP without bleomycin) was suggested to reduce the risk of early death in this setting [201].

7.5 Restaging and further treatment

7.5.1 Restaging

Restaging is performed by imaging investigations and re-evaluation of tumour markers. At marker decline and stable or regressive tumour manifestation, chemotherapy will be completed (three or four cycles, depending on

the initial stage) [34, 203, 204]. In the case of marker decline, but growing metastases, resection of the tumour is obligatory after termination of induction therapy, other than in an emergency, according to local tumour growth [205].

Only with documented marker increase after two courses of chemotherapy is an early crossover of therapy to a completely new regimen indicated. These patients are usually candidates for new drug trials [198, 206]. Patients with a low-level hCG marker plateau post-treatment should be observed to see whether complete normalisation occurs. In patients with a low plateau serum AFP level after chemotherapy, surgery of residual masses should be performed, with post-surgery AFP monitoring. Salvage chemotherapy is indicated for documented marker rise only [207, 208].

7.5.2 **Residual tumour resection**

7.5.2.1 *Seminoma*

A residual mass of seminoma should not be primarily resected, irrespective of the size, but controlled by imaging investigations and tumour markers [209-215].

FDG-PET has a high negative predictive value in patients with residual masses after treatment of seminoma. False positive results are less frequent when scans are scheduled > 2 months after chemotherapy. In patients with residuals of > 3 cm, FDG-PET should be performed in order to gain more information on the viability of these residuals. In patients with residuals of < 3 cm, the use of FDG-PET is optional [49].

In the case of a post-chemotherapy mass that is still positive at reclassification FDG-PET with no volume increase, a second FDG-PET should be performed 6 weeks later. Alternatively, a biopsy should be taken to ascertain persistent disease. In these cases as well as in those with progressive disease (i.e. a growing mass which up-takes contrast medium at CT scans or radionuclide tracer at FDG-PET), salvage therapy is indicated (usually chemotherapy or radiotherapy) [216-220]. Patients with persistent and progressing hCG elevation after 1st line chemotherapy should immediately proceed with salvage chemotherapy. Progressing patients without hCG progression should undergo histological verification (e. g. by biopsy or mini-invasive or open surgery) before salvage chemotherapy is given.

When RPLND is indicated, this should be performed in referral centres, as residuals from seminoma may be difficult to remove due to intense fibrosis [219]. Ejaculation may be preserved in these cases [221].

7.5.2.2 *Non-seminoma*

Following first-line BEP chemotherapy, only 6-10% of residual masses contain viable cancer, 50% contain mature teratoma, and 40% contain necrotic-fibrotic tissue [222].

FDG-PET is not indicated to re-stage patients after chemotherapy [52]. In cases of complete remission after 1st line chemotherapy (no visible tumour), tumour resection is not indicated [223-227].

Residual tumour resection is mandatory in all patients with a residual mass > 1 cm in the short axis at cross-sectional CT imaging [224, 225, 228-237].

The role of surgery is debated in patients with retroperitoneal residual lesions < 1 cm. There is still a risk of residual cancer or teratoma although the vast majority of patients (> 70%) harbour fibro-necrotic tissue [238, 239]. Proponents of PC-RPLND for all patients refer to the fact that both teratoma and vital malignant germ cell tumours are still found after radiologic complete remission in lesions < 10 mm [240]. The alternative is to put patients with residual disease < 1 cm on an observation protocol based on recurrence data of 6-9% depending on the time of follow-up [226, 227]. In the series with the longer observation of 15.5 years, 12 of 141 patients (9%) relapsed after having achieved a complete response after primary treatment [227], but eight of the 12 relapsing patients were cured. Therefore, patients treated with 1st line chemotherapy should be informed about this life-long risk of recurrence in the order of 10% before consenting to observe residual lesions < 1 cm. Patients after salvage chemotherapy or high-dose chemotherapy in 1st or subsequent salvage situations harbour vital tumour at a much higher rate [241]. Therefore, there is an indication to perform surgery in salvage patients even with residual disease < 1 cm [226, 227].

If residual surgery is indicated, all areas of primary metastatic sites must be completely resected within 2-6 weeks of completion of chemotherapy. If technically feasible, a bilateral nerve-sparing procedure should be performed. There is growing evidence that “template” resections with unilateral preservation of nerves in selected patients yield equivalent long-term results compared to bilateral systematic resections in all patients. The mere resection of the residual tumour (so called “lumpectomy”) should not be performed. [223, 227-229, 238, 239, 242-250].

In persistent larger volume retroperitoneal disease, all areas of primary metastatic sites must be completely resected within 2-6 weeks of completion of chemotherapy. If technically feasible, a nerve-sparing procedure should be performed [223, 227-229, 238, 239, 242-246].

Laparoscopic RPLND may yield similar outcomes to the open procedure in very selected cases of very low residual disease and in very experienced hands, but it is not recommended outside a specialised laparoscopic centre [251-253].

7.5.3 Timing of surgery in the case of multiple sites

In general, residual surgery should start at the location with the highest volume of residual disease. The histology may diverge in different organ sites [231]. In cases of retroperitoneal and lung residual masses, the presence of fibro-necrotic tissue in the retroperitoneum is associated with a probability as high as 90% that lung masses contain the same histology [254].

Resection of contralateral pulmonary lesions is not mandatory in case pathologic examination of the lesions from the first lung shows complete necrosis. However, discordant histologies between both lungs may occur in up to 20% [255, 256].

7.5.3.1 Quality and intensity of surgery

Post-chemotherapy surgery is always demanding. Most of the time, post-chemo RPLND does not require further interventions on abdominal or retroperitoneal organs. About a third of patients may require a planned intervention where removal of organs affected by the disease (for example kidney, psoas muscle or gross vessels) are provided and followed by ad hoc reconstructive surgery (e.g. vascular interventions such as vena cava or aortic prostheses) [257, 258]. In patients with intermediate or poor risk and residual disease > 5 cm the probability of vascular procedures is as high as 20% [259]. This intense ("maximal") surgery must therefore be referred to specialised centres capable of interdisciplinary surgery (hepatic resections, vessel replacement, spinal neurosurgery, thoracic surgery). Patients treated within such centres benefit from a significant reduction in perioperative mortality from 6% to 0.8% [13]. In addition, specialised urologic surgeons are capable of reducing the local recurrence rate from 16% to 3% with a higher rate of complete resections [14].

7.5.3.2 Salvage and desperation surgery

Surgery of resectable disease after salvage treatment remains a potentially curative option in all patients with any residual mass following salvage chemotherapy. Survival after surgery and first salvage chemotherapy was improved (70% at 10 years) following taxane-containing regimens [260]. Also, in the case of extensive salvage chemotherapy, surgery remains a fundamental tool to achieve durable complete remissions in up to 20% of patients [261, 262].

Desperation surgery refers to resection of non-responsive or progressive (e.g. rising markers) disease following salvage chemotherapy. When the disease is resectable, a significant proportion of these patients can be rendered disease-free in the long term [263].

7.5.3.3 Consolidation chemotherapy after secondary surgery

After resection of necrosis or mature/immature teratoma, no further treatment is required. In cases of incomplete resection of viable cancer, two adjuvant cycles of conventionally dosed cisplatin-based chemotherapy may be given in certain subgroups (e.g. 'poor prognosis' patients) [247] (caution: cumulative doses of bleomycin). After complete resection of 'vital' tumour < 10% of the total volume, especially in patients in an initially good prognosis group according to IGCCCG, the relapse rate is very low and adjuvant chemotherapy is not beneficial for preventing further relapse [264]. The prognosis will definitely deteriorate if vital malignant neoplasm is found in resection specimens after second- and third-line chemotherapy. In this latter situation, post-operative chemotherapy is not indicated and is unable to improve the prognosis [239, 265].

7.5.4 Systemic salvage treatment for relapse or refractory disease

Cisplatin-based combination salvage chemotherapy will result in long-term remissions in about 50% of the patients who relapse after first-line chemotherapy, but the results are highly dependent on several prognostic factors [266]. The regimens of choice are four cycles of a triplet regimen including cisplatin and ifosfamide plus a third agent: etoposide (PEI/VIP), paclitaxel (TIP), or potentially gemcitabine (GIP) (Table 7.2) [267]. No randomised trial has ever compared these regimens. Due to their potentially lethal risk of haematological toxicity, these regimens should be used with G-CSF support and by well-trained oncologists.

The only available randomised trial comparing standard-dose versus high-dose chemotherapy plus transplant in the salvage setting showed no benefit in OS in patients treated with 3 cycles of vinblastine, ifosfamide, and cisplatin (VeIP) plus 1 cycle of consolidation high-dose chemotherapy, compared with 4 cycles of VeIP [268]. At present, it is impossible to determine whether conventionally dosed cisplatin-based combination chemotherapy is sufficient as first-salvage treatment or whether early intensification of first-salvage treatment with high-dose chemotherapy should be used. However, there is evidence from large retrospective analyses that there are different prognostic groups in the case of relapse after first-line

chemotherapy [269-271], and the Lorch-Beyer score has resulted in 5 prognostic subgroups (Table 7.3). A second large analysis in this cohort of 1600 patients showed an improvement of about 10-15% in OS in patients from all prognostic subgroups when treated with high-dose salvage therapy compared to standard dose therapy. To prospectively confirm this finding, an international randomised trial of high-dose versus conventional dose chemotherapy in patients with first-line relapse is planned (Tiger trial). If high-dose chemotherapy is used as a salvage treatment, sequential treatment cycles of high-dose carboplatin and etoposide HD-CE should be preferred to a single high-dose regimen because the former is associated with less toxicity-related deaths [272].

It is clearly of the utmost importance that these rare patients with relapse are treated within clinical trials and at experienced centres.

Table 7.2: Standard PEI/VIP, TIP and GIP chemotherapy (interval 21 days)

Chemotherapy agents	Dosage	Duration of cycles
PEI/VIP		
Cisplatin*	20 mg/m ²	Days 1-5
Etoposide	75-100 mg/m ²	Days 1-5
Ifosfamide†	1.2 g/m ²	Days 1-5
TIP		
Paclitaxel	250 mg/m ² ^{xx}	24 hour continuous infusion day 1
Ifosfamide†	1.5 g/m ²	Days 2-5
Cisplatin*	25 mg/m ²	Days 2-5
GIP		
Gemcitabine	1000 mg/m ²	Day 1 + 5
Ifosfamide	1200 mg/m ²	Days 1-5
Cisplatin	20 mg/m ²	Days 1-5

PEI/VIP = cisplatin, etoposide, ifosfamide; TIP = paclitaxel, ifosfamide, cisplatin; GIP = gemcitabine, ifosfamide, cisplatin

* Plus hydration.

† Plus mesna protection.

^{xx} An MRC schedule uses paclitaxel at 175 mg/m² in a 3 hour infusion [273].

The International Prognostic Factors Study Group score comprised of 7 important factors is listed in Table 7.3 (seminoma vs. non-seminoma histology, primary tumour site, response to initial chemotherapy, duration of progression-free interval, AFP marker level at salvage, hCG marker level at salvage, and the presence of liver, bone, or brain metastases at salvage). Using these factors, 5 risk groups (very low risk = -1 points; low risk = 0 points; intermediate-risk = 1-2 points, high risk = 3-4 points; and very high risk ≥ 5 points) were identified with significant differences in PFS and OS. Table 4.3 illustrates the 5 risk groups and the corresponding 2-year PFS and 3-year OS rates [274].

Table 7.3: The International Prognostic Factors Study Group Score Construction [270]

Points	-1	0	1	2	3
Variable					
Histology	Seminoma	Non-seminoma			
Primary site		Gonadal	Retroperitoneal		Mediastinal
Response		CR/PRm-	PRm+/SD	PD	
PFI		> 3 months	≤ 3 months		
AFP salvage		Normal	< 1000	1000	
hCG salvage		< 1000	1000		
LBB		No	Yes		

AFP = alpha-fetoprotein; hCG = human chorionic gonadotrophin; LBB = liver, bone, brain metastases; PFI = progression-free interval.

Table 7.4: PFS and OS estimates for all patients according to IGCCCG-2 prognostic score [270]

	n	%	HR	2-year PFS	3-year OS
Score (n=1435)					
Very Low	76	5.30	1	75.1	77.0
Low	257	17.9	2.07	52.6	69.0
Intermediate	646	45.0	2.88	42.8	57.3
High	351	24.5	4.81	26.4	31.7
Very High	105	7.3	8.95	11.5	14.7
Missing	159				

IGCCCG = International Germ Cell Cancer Collaborative Group; OS = overall survival; PSF = progression-free survival.

7.5.5 Second relapse

There are no randomised trials for patients with second relapse; however, conventional therapy does not appear to be very effective. For patients having received two series of conventionally dosed therapy (first-line and first salvage), HD chemotherapy with autologous stem cell support should be used [270]. Even with HD-therapy the curative chance is only 20-25%.

Refractory disease: Patients relapsing within 4-8 weeks after platinum-based therapy or who are progressing despite platinum-based therapy as well as those relapsing shortly after HD-CTX are considered cis-platinum refractory. For those patients, combinations of gemcitabine and oxaliplatin or the triple combination of gemcitabine, oxaliplatin and paclitaxel have resulted in response rates of 25-45%. Cisplatin re-challenge in association with gemcitabine and paclitaxel, could be considered in patients with good renal function [275]. Those patients with a good response undergoing subsequent resection of residual tumour lesions may still have a 15-20% chance of long-term cure [261].

7.5.5.1 Late relapse (≥ 2 years after end of first-line treatment)

Late relapse is defined as recurrence more than 2 years following cure after chemotherapy for metastatic TC, with, or without, residual tumour surgery and occurs, according to a pooled analysis, in 1.4% and 3.2% in seminoma and non-seminoma patients, respectively [276, 277]. If feasible, all lesions of late relapsing non-seminoma patients should be removed by radical surgery.

Patients with rapidly rising hCG may benefit from induction salvage chemotherapy before complete resection, but in most patients surgery should be performed irrespective of the level of their tumour markers in order to completely resect all undifferentiated germ-cell tumour, mature teratoma with or without somatic transformation [138, 278, 279].

Survival strongly depends on the histology of the removed lesions rather than on the initial germ cell cancer. Interestingly, in a population-based study all late-relapsing seminoma patients had viable germ cell tumour, whereas teratoma or necrosis was found in half of the patients with initial non-seminoma [280].

If the lesions are not completely resectable, biopsies should be obtained for histological assessment, and salvage chemotherapy should be initiated according to the histological results. In these cases, consultation of an experienced pathologist is required to avoid misinterpretation of the therapeutic morphological changes in the germ cell neoplasms [281]. If the patient responds to salvage chemotherapy, secondary surgery should be conducted whenever possible. In the case of unresectable, but localised, refractory disease, stereotactic or conventional radiotherapy may be considered. To avoid excess mortality, late relapses should be treated only at centres experienced in managing such patients [282].

7.5.5.2 Treatment of brain metastases

Brain metastases occur in the frame of a systemic relapse and rarely as an isolated relapse. The long-term survival of patients presenting with brain metastases at initial diagnosis is poor (30-50%), but it is even poorer when brain metastasis develops as recurrent disease (the 5-year survival-rate is 2-5%) [283, 284]. Chemotherapy is the initial treatment in this case, and some data support the use of consolidation radiotherapy, even in the case of a total response after chemotherapy [285]. Surgery can be considered in the case of a persistent solitary metastasis, depending on the systemic state, the histology of the primary tumour and the location of the metastasis.

7.5.6 Guidelines for the treatment of metastatic germ cell tumours

	LE	GR
Low volume NSGCT stage IIA/B with elevated markers should be treated like 'good or intermediate prognosis' advanced NSGCT, with three or four cycles of BEP.	2	A
In stage IIA/B without marker elevation, histology can be gained by RPLND or biopsy. A repeat staging can be performed after six weeks of surveillance before final decision on further treatment.	3	B
In metastatic NSGCT (\geq stage IIC) with a good prognosis, three courses of BEP is the primary treatment of choice.	1	A
In metastatic NSGCT with an intermediate prognosis, the primary treatment of choice is four courses of standard BEP.	1	A
In metastatic NSGCT with a poor prognosis, the primary treatment of choice is one cycle of BEP, followed by tumour marker assessment after 3 weeks: in the case of an unfavourable decline, chemotherapy intensification should be initiated; in the case of a favourable decline, BEP should be continued up to a total of four cycles.	1	A
Surgical resection of residual masses after chemotherapy in NSGCT is indicated in the case of visible residual masses and when serum levels of tumour markers are normal or normalising.	2	A
Seminoma CSII A/B can initially be treated with radiotherapy. When necessary, chemotherapy can be used as a salvage treatment with the same schedule as for the corresponding prognostic groups of NSGCT.	2	B
In seminoma stage CS IIA/B, chemotherapy (3 x BEP or 4 x EP, in good prognosis) is an alternative to radiotherapy. It appears that 3 x BEP or 4 x EP achieve a similar level of disease control.	3	B
Seminoma stage IIC and higher should be treated with primary chemotherapy according to the same principles used for NSGCT.	1	A

EP = eposide, cisplatin; GR = grade of recommendation; NSGCT = non-seminomatous germ cell tumour; BEP = cisplatin, eposide, bleomycin; RPLND = retroperitoneal lymph node dissection.

8. FOLLOW-UP AFTER CURATIVE THERAPY

8.1 Follow-up care for cancer patients

There is no consensus on a standardised follow-up of patients treated for germ-cell cancer.

8.2 General considerations

The following considerations apply in a general manner for the selection of an appropriate schedule and testing in the follow-up of all stages of testis tumour.

- Most recurrences after curative therapy will occur in the first 2 years; surveillance should therefore be most frequent and intensive during this time.
- Late relapses can occur beyond 5 years, and therefore yearly follow-up for life may be advocated.
- After RPLND, relapse in the retroperitoneum is rare, the most likely site of recurrence being the chest.
- The value of a plain radiography chest has been recently questioned in the follow-up of patients with disseminated disease after complete remission [286, 287].
- CT of the chest has a higher predictive value than plain radiography chest [287].
- The results of therapy are dependent on the bulk of disease; thus an intensive strategy to detect asymptomatic disease may be justifiable.
- After chemotherapy or radiotherapy, there is a long-term risk of the development of secondary malignancies.
- Exposure to diagnostic X-rays causes second malignancies [288]. Thus, the frequency of CT scans should generally be reduced and any exposure to X-rays should be well justified in a patient cohort with a very long life-expectancy after successful treatment.
- CT can be substituted by MRI. However, MRI is a protocol-dependent method and, thus, should be performed in the same institution with a standardised protocol.
- With special expertise, US may be used as a method to screen the retroperitoneum during follow-up.

However, the method is very much dependent on the investigator and cannot be recommended as the standard method during follow-up.

- Longer follow-up in patients after radiotherapy and chemotherapy is justified to detect late toxicities (e.g. cardio-vascular, endocrine).

A number of interdisciplinary organisations have presented recommendations for follow-up of testicular cancer patients [289-291]. The follow-up tables below (Tables 8.1 through 8.4) present the minimum recommendations of the expert opinions of the guideline authors.

8.3 Follow-up: stage I non-seminoma

Approximately 5% of patients with CS1 NSGCT present with elevated levels of tumour markers after orchiectomy, and up to 25-30% relapse during the first 2 years [7, 128, 130, 131, 171, 292-295]. The follow-up schedule will differ depending on which of the three possible treatment strategies was chosen:

- surveillance;
- nerve-sparing RPLND;
- adjuvant chemotherapy.

8.3.1 Follow-up investigations during surveillance

The results of a surveillance policy depend upon a careful pre-operative staging procedure and follow-up management. In a 'wait and see' policy, relapses will occur in 30% of cases. Of these relapses, 80% will occur in the first 12 months after orchiectomy, and approximately 12% during the second year. The median time to relapse is 6 months (range 1-62 months), but relapses after 3-5 years, and even later, can still occur, with an annual rate of 4% [108, 109]. Relapse occurs mainly in the retroperitoneum: approximately 70% of patients have evident metastases in the retroperitoneum, and 10% in the mediastinum and lungs [296]. Sometimes the only indication is an elevated level of tumour markers.

A randomised trial of two versus five CTs has been published by the MRC recommending the reduction of imaging during surveillance in this stage to one CT scan at 3 months after orchiectomy, and another at 12 months. The trial, with a cohort of 414 patients, was powered to exclude a 3% probability of detecting a patient during surveillance only, with a relapse presenting already-metastatic disease with 'intermediate' or 'poor' prognosis features. Relapses were detected in 15% with two CTs, and 20% with five CTs; 1.6% of these patients had 'intermediate' or 'poor' prognostic features. Only 10% of patients had high-risk features (vascular invasion). In summary, this first randomised trial yielded level 1 evidence for a minimum follow-up in patients with CS1 non-seminoma [142]. The recommended follow-up schedule (Table 8.1) includes the minimum requirements for imaging, and adds recommendations for other surveillance tests [296].

Table 8.1: Recommended minimum follow-up schedule in a surveillance policy: stage I non-seminoma [296]

Procedure	Year			
	1	2	3	4-5
Physical examination	4 times	4 times	4 times	Once/year
Tumour markers	4 times	4 times	4 times	Once/year
Plain radiography chest	Twice		Twice	
Abdominopelvic CT	Twice (at 3 and 12 months)		Once in year 2 (at 24 months) Once in year 3 (at 36 months)	

CT= computed tomography.

8.3.2 Follow-up after nerve-sparing RPLND

Retroperitoneal relapse after a properly performed nerve-sparing RPLND is rare. RPLND should eliminate the retroperitoneal nodes as a site of relapse and thus the need for repeated abdominal CTs. The US Testicular Cancer Intergroup study data show retroperitoneal relapse in 7/264 patients with pathological stage I disease (and 20 pulmonary relapses); four of these seven had no marker elevation [297]. In the Indiana series, only one relapse in 559 cases was reported [298]. If a relapse occurs, it is generally in the chest, neck or at the margins of the surgical field.

Pulmonary relapses occur in 10-12% of patients, and more than 90% of those relapses occur within 2 years of RPLND [55, 299]. However, the low rate of retroperitoneal relapse after RPLND can only be achieved by surgery in specialised centres, as shown by the high in-field relapse rate (7/13 relapses) in the German randomised trial

of RPLND versus one course of BEP [135]. The recommended minimum follow-up schedule is shown in Table 8.2.

Table 8.2: Recommended minimum follow-up schedule after retroperitoneal lymphadenectomy or adjuvant chemotherapy: stage I non-seminoma

Procedure	Year				
	1	2	3	4-5	6-10
Physical examination	4 times	4 times	4 times	Once/year	Once/year
Tumour markers	4 times	4 times	4 times	Once/year	Once/year
Plain radiography chest	Twice	Twice	Twice		
Abdominopelvic CT	Once	Once	Once	Once/year	

CT = computed tomography.

8.3.3 Follow-up after adjuvant chemotherapy

Prospective reports with long-term follow-up after adjuvant chemotherapy have shown a low relapse rate of about 3% [128-131]. In a randomised trial with one course of BEP versus RPLND, the relapse rate with adjuvant chemotherapy was 1% (2/174 patients, one with marker relapse, one with mature teratoma in the retroperitoneum) [135]. The need for repeated and long-term assessment of the retroperitoneum is still not clear. Owing to the risk of developing a late, slow-growing teratoma in the retroperitoneum after adjuvant chemotherapy, an abdominal CT should still be performed (see Table 8.2).

8.4 Follow-up: stage I seminoma

The majority of patients with seminoma (70-80%) present with clinical stage I disease at diagnosis. In 15-20% of cases, there is nodal radiological involvement at the level of the retroperitoneum, and only 5% of patients present with distant metastasis.

The relapse rate varies between 1% and 20%, depending on the post-orchietomy therapy chosen. Only up to 30% of seminomas present with elevation of hCG at diagnosis or in the course of the disease. Consequently, in most cases, measurement of blood markers will not be a reliable test for follow-up [300]. The treatment options post-orchietomy in stage I seminoma are surveillance or adjuvant carboplatin chemotherapy.

8.4.1 Follow-up after radiotherapy

Low doses of radiotherapy (20-24 Gy) limited to the retroperitoneal or the paraaortic and ipsilateral field achieve an OS rate of approximately 99% at 5-10 years [108-110, 301, 302]. The rate of relapse is 1-2% and the most common time of presentation is within 18 months of treatment [108, 111, 302-304], although late relapses have also been described [278]. The site of relapse is mainly at the supradiaphragmatic lymph nodes, mediastinum, lungs or bones. In a small proportion of cases, the tumour will relapse in the inguinal or external iliac nodes. After para-aortic field RT there is also a pelvic node relapse pattern.

The side-effects of radiotherapy include temporary impaired spermatogenesis, GI symptoms (peptic ulceration), and induction of second malignancies [303, 305, 306]. Up to 50% of patients can develop moderate toxicity grade I-II [300]. The follow-up schedule is described in Table 8.3.

Table 8.3: Recommended minimum follow-up schedule for post-orchietomy surveillance, radiotherapy or chemotherapy: stage I seminoma [295]

Procedure	Year		
	1	2	3-5
Physical examination	3 times	3 times	Once/year
Tumour markers	3 times	3 times	Once/year
Plain radiography chest	Twice	Twice	
Abdominopelvic CT	Twice	Twice	at 36 and 60 months

CT = computed tomography.

8.4.2 Follow-up during surveillance

The actuarial risk of relapse at 5 years ranges between 6% (low risk) and 20% [114, 307-311]. There is no increased risk of death. The median time to relapse ranges from 12-18 months, but up to 29% of relapses can develop later than this [99, 312]. The sites of relapse are the PA lymph nodes in up to 82% of cases; the pelvic

lymph nodes, inguinal nodes and lungs can also be affected [99, 134, 313-316]. Due to the high and often late rate of relapse, close and active follow-up is mandatory for at least 5 years [307] (see Table 8.3).

8.4.3 Follow-up after adjuvant chemotherapy

One or two courses of carboplatin-based chemotherapy is an effective alternative treatment in stage I seminoma. The relapse rate is 1.9-4.5%. In general, this treatment is well tolerated, with only mild, acute and intermediate-term toxicity [307, 308]. Long-term data on late relapses and survival are missing (see Table 8.3).

8.5 Follow-up: (metastatic) disease

The more advanced the nodal stage of the disease, the higher the likelihood of recurrence [170]. In general, the primary tumour bulk governs the outcome for patients with NSGCT [312]. In stage II NSGCT, regardless of the treatment policy adopted, excellent survival rates of 97% are reached provided that relapse is identified as soon as possible [140, 165, 172].

In advanced metastatic germ-cell tumours, the extent of the disease correlates with the response to therapy and with survival. The combination of cisplatin-based chemotherapy and surgery (aggressive multimodality) achieves cure rates of between 65% and 85%, depending on the initial extent of disease [310, 311]. Complete response rates to chemotherapy are in the order of 50-60% [310]; another 20-30% of patients could be disease-free with post-chemotherapy surgery [317].

The main reasons for failure of therapy in advanced NSGCT are [34, 309, 318]:

- the presence of bulky disease not responding completely to chemotherapy;
- unresectable residual teratoma after chemotherapy;
- the presence or development of chemoresistant non-germ elements, which account for 8.2% of cases.

Table 8.4 presents the recommended minimum follow-up schedule in advanced NSGCT and seminoma.

Table 8.4: Recommended minimum follow-up schedule in metastatic NSGCT and seminoma

Procedure	Year			
	1	2	3-5	Thereafter
Physical examination	4 times	4 times	Twice/year	Once/year
Tumour markers	4 times	4 times	Twice/year	Once/year
Plain radiography chest	4 times	4 times	Twice/year	Once/year
Abdominopelvic CT*†	Twice	Twice	Once/year	As indicated
Chest CT†‡	Once/year	Once/year	Once/year	As indicated
Brain CT§	Once/year	Once/year	Once/year	As indicated

CT = computed tomography.

* An abdominal CT must be performed at least annually if teratoma is found in the retroperitoneum.

† If the post-chemotherapy evaluation in a seminoma patient shows any mass > 3 cm, the appropriate CT should be repeated 2 and 4 months later to ensure that the mass is continuing to regress. If available, FDG-PET/CT can be performed.

‡ A chest CT is indicated if abnormality is detected on a plain radiography chest and after pulmonary resection.

§ In patients with headaches, focal neurological findings, or any central nervous system symptoms.

8.6 Quality of life and long-term toxicities after cure for testicular cancer

The vast majority of patients will be cured and 5-year relative survival rates approximate 95% in Western Europe. Furthermore, TC patients are usually between 18 and 40 years at diagnosis such that life expectancy after cure extends over several decades [319]. Patients should be informed before treatment of common long-term toxicities, which are probably best avoided by adherence to international guidelines. Treatment of stage I TC is controversial with some experts advocating surveillance for all, thereby avoiding unnecessary adjuvant chemotherapy [126], whereas others highlight the importance of patient autonomy and consider the prospect of avoiding salvage treatment with its known long-term toxicities as quite appealing [320]. Unfortunately, we do not know which treatment spares most patients long-term toxicities, which so far seem to be absent or mild after adjuvant chemotherapy [131, 139, 321].

During follow-up, patients should be screened and treated for known risk factors such as high blood pressure, hyperlipidaemia and testosterone deficiency. When follow-up by the TC expert is discontinued, a written cancer survivorship plan addressing late toxic effects, lifestyle recommendations, recurrence risk, and cancer-specific follow-up might be helpful [277, 322]. The following overview is not complete and interested readers are referred to review articles on this topic [319, 322, 323].

8.6.1 **Second malignant neoplasms (SMN)**

Treatment-induced SMN usually occur after the first 10 years [322]. The risk for solid SMN increases with younger age at radio- or chemotherapy and remains significantly elevated for at least 35 years [111, 115, 324-326]. RT-related SMN are primarily localised within or close to the RT field (colon, stomach, pancreas, bladder and the urinary tract) [111, 112, 115, 116, 325-328]. Fung et al. demonstrated that modern cisplatin-based chemotherapy was associated with a 40% increased risk of a solid SMN [329].

8.6.2 **Leukaemia**

In a series of 40,576 TC survivors, the observed/expected ratio for developing a leukaemia, mostly acute myeloid (AML) and lymphoblastic leukaemias was 2.6 (95% CI, 2.1 to 3.2) [330]. The risk of AML seems to be both related to the dose of cisplatin and etoposide. Doses of etoposide exceeding 2 g/m² have been shown to increase the subsequent risk of AML considerably [331]. It is important to keep in mind that the majority of TC patients do not receive much lower doses of etoposide such that the absolute risk of AML after three to four courses of BEP is very low, and in patients requiring high-dose chemotherapy with cumulative etoposide doses exceeding this threshold, less than 1.5% have been reported to suffer from AML. There is a cumulative dose-disease relationship regarding cisplatin and AML. Chemotherapy-induced leukaemia is usually diagnosed within the first 10 years after treatment for TC and has a very poor prognosis [332].

8.6.3 **Infections**

Chemotherapy-treated testicular cancer survivors (TCSs) have a higher risk of dying from infections than the normal population, SMR 2.48, 95% CI: 1.70 to 3.50 [333]. This is possibly due to long-term depression of the bone-marrow, but also complications of subsequent salvage treatment (which was not reliably registered) or extensive or subsequent surgical treatment might lie behind these numbers. Furthermore, asymptomatic pulmonary fibrosis by mediastinal radiotherapy and/or bleomycin may render TCSs vulnerable to potentially deadly pneumonias many years after treatment.

8.6.4 **Pulmonary complications**

Chemotherapy exposed TCSs have a nearly 3-fold increased risk of dying of pulmonary diseases than the normal population [333]. Bleomycin-induced lung toxicity may affect 7% to 21% of patients in the long-term, resulting in death in 1%-3% [334]. TCSs treated with high cumulative cisplatin doses and/or pulmonary surgery, have a poorer pulmonary function than those cured by surgery only [335]. Intriguingly, pulmonary complications were associated with the cumulative cisplatin dose and not to the dose of bleomycin.

8.6.5 **Cardiovascular toxicity**

Mortality from cardiovascular disease (CVD) is higher in TCSs than in the general population [333, 336]. Furthermore, CVD is more common in chemotherapy-treated TCSs than in those who underwent surgery only [134, 315]. The metabolic syndrome is a strong predictor for CVD and its components, i.e. hypertension, obesity and hypercholesterolemia, increase with treatment intensity [316, 337]. Circulating residual serum platinum might exert endothelial stress [338].

8.6.6 **Raynaud-like phenomena**

Chemotherapy-related Raynaud-like phenomena were reported before the introduction of cisplatin and are usually ascribed to the application of bleomycin [339, 340]. Cisplatin is believed to contribute to cold-induced vasospasms, as Vogelzang et al. reported that the incidence of Raynaud's phenomenon was higher after treatment with CVB than after vinblastine and bleomycin only (41% vs. 21%, respectively) [341].

8.6.7 **Neurotoxicity**

Cisplatin induces a symmetric dose-dependent sensory, distal, length-dependent "glove and stocking" paraesthesias, affecting 29% of TCSs who received cisplatin-based chemotherapy as opposed to 10% after orchiectomy alone [342]. Application of five or more cycles increases the frequency of this symptom to 46%. Paclitaxel-induced acute neuropathy consists of an acute pain syndrome, which usually develops within three days of paclitaxel administration, or within a week. Platinum is measurable in the serum of TCSs many years after its application and the intensity of paraesthesias is more strongly associated with platinum serum level than with the cumulative dose of applied cisplatin [338].

8.6.8 **Ototoxicity**

Cisplatin-induced ototoxicity comprises tinnitus and hearing impairment, particularly of high frequencies of 4000 Hz and higher, and is caused by damage to the outer hair cells in the inner ear [343-345]. Both hearing impairment and tinnitus are considerably increased after application of 50 mg/m² cisplatin over two days as compared to 20 mg/m² over five days (odds ratio 5.1 and 7.3, respectively), indicating a higher impact of serum

peak concentrations than cumulative doses [342]. A significant association between GST genotypes and the risk of cisplatin-induced ototoxicity has been demonstrated [346, 347]. Hopefully, increasing insight into the pathogenesis of and vulnerability for this complication will lead to more individualised treatment in the future.

8.6.9 **Nephrotoxicity**

Cisplatin-based chemotherapy may lead to long-term renal function impairment in 20-30% of TCSs [342-345]. In testicular cancer patients, reduced renal elimination of cisplatin and bleomycin might increase the risk of other toxicities, e.g. bleomycin-related pneumonitis [348, 349].

8.6.10 **Hypogonadism**

Testicular endocrine dysfunction comprises insufficient testosterone (T) production and/or compensatory increased Luteinizing Hormone (LH) levels. Subnormal testosterone levels have been reported in TCs treated with chemotherapy compared with surgery only or the general population [322, 350].

8.6.11 **Fatigue**

Chronic fatigue (CF) is described as a subjective feeling of emotional, physical and/or cognitive tiredness that is not relieved by rest, persisting for more than 6 months. Significantly higher levels of C-reactive protein and interleukin-1 receptor antagonist are measured in TCSs with CF [351]. Also, a significantly higher frequency of CF (16%) was reported in a cross-sectional Norwegian study of long-term TCSs a median of 12 years after treatment for TC when compared with the age-matched Norwegian population (10%) [352]. Of note; the prevalence of CF increased from 15% to 27% during 10 years in long-term TCSs [353].

8.6.12 **Quality of life**

Quality of life (QoL) is transiently reduced by chemotherapy, during which patients experience a loss of appetite, increased fatigue, increased dyspnoea, reduced social-, physical- and role-functions [354]. When comparing three or four cycles of BEP in good risk patients, all outcomes favour treatment with three courses [184]. After 1 and 2 years, one third of patients reported an improvement in global QoL after chemotherapy, while one fifth of patients reported deterioration, with no difference between treatment groups. In adjuvant treatment of non-seminoma stage I patients, there was no difference in short-term or long-term (5 year) QoL between RPLND or one course of BEP [355].

9. TESTICULAR STROMAL TUMOURS

9.1 **Classification**

Non-germ-cell tumours of the testicle include sex cord/gonadal stromal tumours and miscellaneous non-specific stromal tumours. The different histological subtypes of testicular tumours are defined according to the WHO classification 2004 (adapted) [32].

9.2 **Leydig cell tumours**

9.2.1 **Epidemiology**

Leydig cell tumours constitute about 1-3% of adult testicular tumours [356, 357] and 3% of testicular tumours in infants and children [357]. These tumours are most common in the third to sixth decade in adults, with a similar incidence observed in each decade. Another peak incidence is seen in children aged between 3 and 9 years. Only 3% of Leydig cell tumours are bilateral [356]. These tumours occur in about 8% of patients with Klinefelter's syndrome [358].

9.2.2 **Pathology of Leydig cell tumours**

Leydig cell tumours are the most common type of sex cord/gonadal stromal tumours. Histopathologically, they are well delineated and usually up to 5 cm in diameter. They are solid, yellow to tan in colour, with haemorrhage and/or necrosis in 30% of cases. Microscopically, the cells are polygonal, with eosinophilic cytoplasm and occasional Reinke crystals, regular nucleus, solid arrangement and capillary stroma. The cells express vimentin, inhibin, protein S-100, steroid hormones, calretinin and cytokeratin (focally) [32].

Approximately 10% of Leydig cell tumours are malignant and present with the following parameters [359, 360]:

- large size (> 5 cm);
- older age;
- increased mitotic activity (> 3 per 10 high-power field [HPF]);

- vascular invasion;
- cytological atypia;
- increased MIB-1 expression;
- necrosis;
- infiltrative margins;
- extension beyond the testicular parenchyma;
- DNA aneuploidy.

9.2.3 **Diagnosis**

Patients either present with a painless enlarged testis or the tumour is found incidentally on US. In up to 80% of cases, hormonal disorders with high oestrogen and oestradiol levels, low testosterone, and increased levels of LH and FSH are reported [361, 362], while negative results are always obtained for the testicular germ cell tumour-markers AFP, hCG, LDH and PLAP. Up to 10% of adult patients present with gynaecomastia [362, 363]. Only 3% of tumours are bilateral [356].

Diagnostic work-up must include markers, hormones (at least testosterone, LH and FSH; if not conclusive, also oestrogen, oestradiol, progesterone and cortisol), US of both testes, and CT of chest and abdomen. On US, it may be possible to observe well-defined, small, hypoechoic lesions with hypervascularisation, however, the appearance is variable and is indistinguishable from germ-cell tumours [364]. The proportion of metastatic tumours in all published case reports is less than 10%. In three old series with long follow-up, 18 metastatic tumours were found in a total of 83 cases (21.7%) [356, 359, 365], while 5 recently published studies with long follow-up reported only 2 metastatic tumours in 156 patients (1.3%) [362, 363, 366-368].

9.3 **Sertoli cell tumours**

9.3.1 **Epidemiology**

Sertoli cell tumours account for fewer than 1% of testicular tumours, and the mean age at diagnosis is around 45 years, with rare cases under 20 years of age [369, 370]. On rare occasions, these tumours may develop in patients with androgen insensitivity syndrome and Peutz-Jeghers syndrome.

9.3.2 **Pathology of Sertoli cell tumours**

These tumours are well circumscribed, yellow, tan or white in colour, with an average diameter of 3.5 cm [369]. Microscopically, the cells are eosinophilic to pale with vacuolated cytoplasm. The nuclei are regular with grooves and inclusions may be present. The arrangement of the cells is tubular or solid; a cord-like or retiform pattern is possible. The stroma is fine with capillaries, but in some cases a sclerosing aspect predominates. The cells express vimentin, cytokeratins, inhibin (40%) and protein S-100 (30%) [369].

The rate of malignancy ranges between 10% and 22%. Signs of a malignant Sertoli tumour are as follows [371, 372]:

- large size (> 5 cm);
- increased mitotic activity (> 5 per 10 HPF);
- pleomorphic nuclei with nucleoli;
- necrosis;
- vascular invasion.

9.3.2.1 **Classification**

Three subtypes have been described [370]:

- Classic Sertoli cell tumour [369];
- Large cell calcifying form with characteristic calcifications [373, 374];
- Sclerosing form [375, 376].

9.3.3 **Diagnosis**

Patients present either with an enlarged testis or the tumour is found incidentally on US. Most classic Sertoli cell tumours are unilateral and unifocal. Hormonal disorders are infrequent, although gynaecomastia is sometimes seen [369]. The testicular tumour-markers AFP, hCG, LDH and PLAP are always negative.

Diagnostic work-up must include tumour markers, hormones (at least testosterone, LH and FSH; if not conclusive, also oestrogen, oestradiol, progesterone and cortisol), US of both testes and CT of chest and abdomen. Sertoli cell tumours are generally hypoechoic on US, but they can be of variant appearance and thus cannot be safely distinguished from germ-cell tumours [370]. Only the large cell calcifying form has a characteristic image with bright echogenic foci due to calcification [377].

Metastatic disease of 12% in classic Sertoli cell tumour has been reported. In general, affected patients are older, tumours are nearly always palpable, and show more than one sign of malignancy [369].

The **large cell calcifying** form is diagnosed in younger men and is associated with genetic dysplastic syndromes (Carney's complex [378] and Peutz-Jeghers syndrome [379] or, in about 40% of cases, endocrine disorders. 44% of cases are bilateral, either synchronous or metachronous, and 28% show multifocality with good prognosis [374].

Up to 20% of the large cell calcifying forms are malignant. It has been suggested that discrimination between an early and late onset type may define a different risk for metastatic disease (5.5% compared to 23%) [370].

The sclerosing subtype is very rare, unilateral, with a mean age around 40 years and metastases are infrequent [376].

9.4 Treatment of Leydig- and Sertoli cell tumours

Asymptomatic, small volume testicular tumours are often misinterpreted as germ-cell tumours, and inguinal orchidectomy is performed. An organ-sparing procedure in every small ultrasound-detected, nonpalpable intraparenchymal lesion is highly recommended in order to obtain a histological diagnosis. The incidence of benign definitive histology is high at approximately 80% [380]. In patients with symptoms of gynecomastia or hormonal disorders, a non-germ-cell tumour should be considered and immediate orchidectomy avoided. In cases with germ-cell tumour in either frozen section or paraffin histology, orchidectomy is recommended as long as a contralateral normal testicle is present.

When diagnosed and treated early, long-term favourable outcomes are seen at follow-up in Leydig cell tumours, even with its potential metastatic behaviour. In stromal tumours with histological signs of malignancy, especially in older patients, orchidectomy and early retroperitoneal lymphadenectomy may be an option to prevent metastases [381] or to achieve long-term cure in stage IIa cases [382]. Prophylactic retroperitoneal lymph node dissection is unjustified for patients with clinical stage I disease without high-risk features [383].

Tumours that have metastasised to lymph nodes, lung, liver or bone respond poorly to chemotherapy or radiation and survival is poor [381]. No recommendations are available for the treatment of these patients.

9.5 Follow-up of Leydig- and Sertoli cell tumours

Without clinical signs of malignancy, an individualised surveillance strategy after orchidectomy is recommended in patients with one, or more, pathological features of malignancy. Follow-up is recommended in all high-risk patients; every 3 to 6 months with physical examination, hormone assays, scrotal and abdominal ultrasonography, chest radiography, and CT [362].

9.6 Granulosa cell tumour

This is a rare tumour with two variants: juvenile and adult. Less than 100 cases are reported with a predominance of the juvenile type.

- The juvenile type is benign. It is the most frequent congenital testicular tumour and represents about 1-5% of all prepubertal testicular neoplasms. The cystic appearance is characteristic of this tumour type [384, 385].
- The average age of the adult type at presentation is 45 years. The typical morphology is a homogeneous, yellow-grey tumour, with elongated cells with grooves in microfollicular and Call-Exner body arrangements [386].

Malignant tumours represent around 20% of cases. Lymphovascular invasion, necrosis, infiltrative borders and size > 4 cm may help in identifying cases with aggressive behaviour. Mitotic counts vary and do not appear to be of prognostic significance [387].

9.7 Thecoma/fibroma group of tumours

These tumours are rare with variable histology such as minimal invasion into surrounding testis, high cellularity, and increased mitotic rate. Their immunoprofile is variable and typically not diagnostic. They seem to be uniformly benign [388].

9.8 Other sex cord/gonadal stromal tumours

Sex cord/gonadal stromal tumours may be incompletely differentiated or in mixed forms.

There is limited experience with incompletely differentiated sex cord/gonadal stromal tumours and no reported

cases of metastasis [32]. In mixed tumour forms, all the histological components should be reported. However, the clinical behaviour most likely reflects the predominant pattern or the most aggressive component of the tumour [389].

9.9 Tumours containing germ cell and sex cord/gonadal stroma (gonadoblastoma)

Some patients with disorders of sex development (DSDs) have abnormal gonadal development with ambiguous genitalia and an increased risk of germ-cell tumours. If the arrangement of the germ cells is in a nested pattern and the rest of the tumour is composed of sex cord/gonadal stroma, the term gonadoblastoma is used. Bilateral tumours are present in 40% of cases. The prognosis correlates with the invasive growth of the germinal component [390, 391].

In the case of a diffuse arrangement of the different components, there are some doubts about the neoplastic nature of the germinal cells and some authors consider them to be entrapped rather than neoplastic [392].

9.10 Miscellaneous tumours of the testis

9.10.1 Tumours of ovarian epithelial types

These tumours resemble epithelial tumours of the ovary. A cystic appearance with occasional mucinous material can be observed. Microscopically, the aspect is identical to their ovarian counterparts, and their evolution is similar to that of the different epithelial ovarian subtypes. Some Brenner types are malignant [32].

9.10.2 Tumours of the collecting ducts and rete testis

These tumours are very rare. Benign (adenoma) and malignant (adenocarcinoma) have been reported, with malignant tumours showing local growth with a mortality rate of 40% within one year [393].

9.10.3 Tumours (benign and malignant) of non-specific stroma

These are very uncommon and have similar criteria, prognosis and treatment to soft tissue sarcomas.

10. REFERENCES

1. Albers P, Albrecht W, Algaba F, et al. European Association of Urology. EAU guidelines on testicular cancer: 2011 update. *Eur Urol* 2011 Aug;60(2):304-19.
<http://www.ncbi.nlm.nih.gov/pubmed/21632173>
2. La Vecchia C, Bosetti C, Lucchini F, et al. Cancer Mortality in Europe, 2000-2004, and an overview of trends since 1995. *Ann Oncol* 2010 Jun;21(6):1323-60.
<http://www.ncbi.nlm.nih.gov/pubmed/19948741>
3. Cancer Incidence in Five Continents, Vol IX. Curado MP, Edwards B, Shin R, et al eds. IARC Scientific Publication 2007, No. 160.
<http://www.iarc.fr/en/publications/pdfs-online/epi/index.php>
4. Engholm G, Ferlay J, Christensen N, et al. NORDCAN--a Nordic tool for cancer information, planning, quality control and research. *Acta Oncol* 2010 Jun;49(5):725-36.
<http://www.ncbi.nlm.nih.gov/pubmed/20491528>
5. Wanderas EH, Tretli S, Fossa SD. Trends in incidence of testicular cancer in Norway 1955-1992. *Eur J Cancer* 1995 Nov;31A(12):2044-8.
<http://www.ncbi.nlm.nih.gov/pubmed/8562163>
6. Jemal A, Siegel R, Ward E, et al. Cancer Statistics, 2009. *CA Cancer J Clin* 2009 Jul-Aug;59(4):225-49.
<http://www.ncbi.nlm.nih.gov/pubmed/19474385>
7. Huyghe E, Matsuda T, Thonneau P. Increasing incidence of testicular cancer worldwide: a review. *J Urol* 2003 Jul;170(1):5-11.
<http://www.ncbi.nlm.nih.gov/pubmed/12796635>
8. Nigam M, Aschebrook-Kilfoy B, Shikanov S, et al. Increasing incidence of testicular cancer in the United States and Europe between 1992 and 2009. *World J Urol* 2014 Jul 17 Epub ahead of print
<http://www.ncbi.nlm.nih.gov/pubmed/25030752>
9. McGlynn KA, Devesa SS, Sigurdson AJ, et al. Trends in the incidence of testicular germ cell tumours in the United States. *Cancer* 2003 Jan;97(1):63-70.
<http://www.ncbi.nlm.nih.gov/pubmed/12491506>

10. Masters JR, Köberle B. Curing metastatic cancer: lessons from testicular germ-cell tumours. *Nat Rev Cancer* 2003 Jul;3(7):517-25.
<http://www.ncbi.nlm.nih.gov/pubmed/12835671>
11. Jones A, Fergus JN, Chapman J, et al. Is surveillance for stage I germ cell tumours of the testis appropriate outside a specialist centre? *BJU Int* 1999 Jul;84(1):79-84.
<http://www.ncbi.nlm.nih.gov/pubmed/10444129>
12. Collette L, Sylvester RJ, Stenning SP, et al. Impact of the treating institution on survival of patients with "poor-prognosis" metastatic nonseminoma. European Organization for Research and Treatment of Cancer Genitourinary Tract Cancer Collaborative Group and the Medical Research Council Testicular Cancer Working Party. *J Natl Cancer Inst* 1999 May;91(10):839-46.
<http://www.ncbi.nlm.nih.gov/pubmed/10340903>
13. Capitanio U, Jeldres C, Perrotte P, et al. Population-based study of perioperative mortality after retroperitoneal lymphadenectomy for nonseminomatous testicular germ cell tumors. *Urology* 2009 Aug;74(2):373-7.
<http://www.ncbi.nlm.nih.gov/pubmed/19501893>
14. Fléchon A, Tavernier E, Boyle H, et al. Long-term oncological outcome after post chemotherapy retroperitoneal lymph node dissection in men with metastatic nonseminomatous germ cell tumour. *BJU Int* 2010 Sep;106(6):779-85.
<http://www.ncbi.nlm.nih.gov/pubmed/20089110>
15. Bosl GJ, Motzer RJ. Testicular germ-cell cancer. *N Engl J Med* 1997 Nov;337(4):242-53.
[No abstract available]
<http://www.ncbi.nlm.nih.gov/pubmed/9227931>
16. Kuczyk MA, Serth J, Bokemeyer C, et al. Alterations of the p53 tumour suppressor gene in carcinoma in situ of the testis. *Cancer* 1996 Nov;78(9):1958-66.
<http://www.ncbi.nlm.nih.gov/pubmed/8909317>
17. Looijenga LH, Gillis AJ, Stoop H, et al. Relevance of microRNAs in normal and malignant development, including human testicular germ cell tumours. *Int J Androl* 2007 Aug;30(4):304-14;discussion 314-15.
<http://www.ncbi.nlm.nih.gov/pubmed/17573854>
18. Reuter VE. Origins and molecular biology of testicular germ cell tumors. *Mod Pathol* 2005 Feb;18(Suppl 2):S51-S60.
<http://www.ncbi.nlm.nih.gov/pubmed/15761466>
19. Jorgensen N, Rajpert-De Meyts E, Main KM, et al. Testicular dysgenesis syndrome comprises some but not all cases of hypospadias and impaired spermatogenesis. *Int J Androl* 2010 Apr;33(2):298-303.
<http://www.ncbi.nlm.nih.gov/pubmed/20132348>
20. Lip SZ, Murchison LE, Cullis PS, et al. A meta-analysis of the risk of boys with isolated cryptorchidism developing testicular cancer in later life. *Arch Dis Child* 2013 Jan;98(1):20-6.
<http://www.ncbi.nlm.nih.gov/pubmed/23193201>
21. Osterlind A, Berthelsen JG, Abildgaard N, et al. Risk of bilateral testicular germ cell tumours in Denmark: 1960-1984. *J Natl Cancer Inst* 1991 Oct;83(19):1391-5.
<http://www.ncbi.nlm.nih.gov/pubmed/1656057>
22. Møller H, Prener A, Skakkebaek NE. Testicular cancer, cryptorchidism, inguinal hernia, testicular atrophy and genital malformations: case-control studies in Denmark. *Cancer Causes Control* 1996 Mar;7(2):264-74.
<http://www.ncbi.nlm.nih.gov/pubmed/8740739>
23. Dieckmann KP, Pichlmeier U. The prevalence of familial testicular cancer: An analysis of two patient populations and a review of the literature. *Cancer* 1997 Nov;80(10):1954-60.
<http://www.ncbi.nlm.nih.gov/pubmed/9366298>
24. Forman D, Oliver RT, Brett AR, et al. Familial testicular cancer: a report of the UK family register, estimation of risk and a HLA class 1 sib-pair analysis. *Br J Cancer* 1992 Feb;65(2):255-62.
<http://www.ncbi.nlm.nih.gov/pubmed/1739626>
25. Weestergaard T, Olsen JH, Frisch M, et al. Cancer risk in fathers and brothers of testicular cancer patients in Denmark. A population based study. *Int J Cancer* 1996 May;66(5):627-31.
<http://www.ncbi.nlm.nih.gov/pubmed/8647624>
26. Dieckmann KP, Loy V, Buttner P. Prevalence of bilateral germ cell tumours and early detection based on contralateral testicular intra-epithelial neoplasia. *Br J Urol* 1993 Mar;71(3):340-5.
<http://www.ncbi.nlm.nih.gov/pubmed/8386582>

27. Peng X, Zeng Z, Peng S, et al. The Association risk of male subfertility and testicular cancer: A systematic review. *PLoS ONE* 4(5):e5591.
<http://www.ncbi.nlm.nih.gov/pubmed/19440348>
28. Greene MH, Kratz CP, Mai PL, et al. Familial testicular germ cell tumors in adults: 2010 summary of genetic risk factors and clinical phenotype. *Endocr Relat Cancer* 2010 Mar;17(2):R109-21.
<http://www.ncbi.nlm.nih.gov/pubmed/20228134>
29. Lutke Holzik MF, Rapley EA, Hoekstra HJet al. Genetic predisposition to testicular germ-cell tumours. *Lancet Oncol* 2004 Jun;5(6):363-71.
<http://www.ncbi.nlm.nih.gov/pubmed/15172357>
30. Dieckmann KP, Hartmann JT, Classen J, et al. Tallness is associated with risk of testicular cancer: evidence for the nutrition hypothesis. *Br J Cancer* 2008 Nov;99(9):1517-21.
<http://www.ncbi.nlm.nih.gov/pubmed/18827809>
31. Dieckmann KP, Hartmann JT, Classen J, et al. Is increased body mass index associated with the incidence of testicular germ cell cancer? *J Cancer Res Clin Oncol* 2009 May;135(5):731-8.
<http://www.ncbi.nlm.nih.gov/pubmed/19002497>
32. WHO histological classification of testis tumours, In: Eble JN, Sauter G, Epstein JI, Sesterhenn IA, eds. *Pathology & Genetics. Tumours of the urinary system and male genital organs*. Lyon: IARC Press, 2004: 218, pp. 212-74.
<http://www.iarc.fr/en/publications/pdfs-online/pat-gen/bb7/index.php>
33. C P. Tumeurs du testicule. Synthèse et recommandations en onco-urologie. [Testicular tumours. Summary of onco-urological recommendations] [Article in French]. *Prog Urol* 1993;2:60-4.
34. Sheinfeld J, Bajorin DF, Solomon M. Management of postchemotherapy residual masses in advanced germ cell tumours. *Urol Clin North Am* 1997;3:18-23.
35. Haugnes HS, Laurell A, Stierner U, et al. High-dose chemotherapy with autologous stem cell support in patients with metastatic non-seminomatous testicular cancer - a report from the Swedish Norwegian Testicular Cancer Group (SWENOTECA). *Acta Oncol* 2012 Feb;51(2):168-76.
<http://www.ncbi.nlm.nih.gov/pubmed/22175254>
36. Fizazi K, Culine S, Kramar A, et al. Early predicted time to normalization of tumor markers predicts outcome in poor-prognosis nonseminomatous germ cell tumors. *J Clin Oncol* 2004 Oct;22(19):3868-76.
<http://www.ncbi.nlm.nih.gov/pubmed/15302906>
37. Fizazi K, Pagliaro L, Laplanche A, et al. Personalised chemotherapy based on tumour marker decline in poor prognosis germ-cell tumours (GETUG 13): a phase 3, multicentre, randomised trial. *Lancet Oncol* 2014 Dec;15(13):1442-50.
<http://www.ncbi.nlm.nih.gov/pubmed/25456363>
38. Leibovitch I, Foster RS, Kopecky KK, et al. Improved accuracy of computerized tomography based clinical staging in low stage nonseminomatous germ cell cancer using size criteria of retroperitoneal lymph nodes. *J Urol* 1995 Nov;154(5):1759-63.
<http://www.ncbi.nlm.nih.gov/pubmed/7563341>
39. Jing B, Wallace S, Zornoza J. Metastases to retroperitoneal and pelvic lymph nodes: computed tomography and lymphangiography. *Radiol Clin North Am* 1982 Sep;20(3):511-30. [No abstract available]
<http://www.ncbi.nlm.nih.gov/pubmed/7051132>
40. Husband JE, Barrett A, Peckham MJ. Evaluation of computed tomography in the management of testicular teratoma. *Br J Urol* 1981 Apr;53(2):179-83.
<http://www.ncbi.nlm.nih.gov/pubmed/7237052>
41. Swanson DA. Role of retroperitoneal lymphadenectomy (RLDN) when patients with nonseminomatous germ cell testicular tumours are at high risk of needing lymph node surgery plus chemotherapy, in Donohue JP (ed.). *Lymph Node Surgery in Urology*. International Society of Urology Reports. Oxford: Isis Medical Media, 1995, pp. 133-140.
42. Ellis JH, Blies JR, Kopecky KK, et al. Comparison of NMR and CT imaging in the evaluation of metastatic retroperitoneal lymphadenopathy from testicular carcinoma. *J Comput Assist Tomogr* 1984 Aug;8(4):709-19.
<http://www.ncbi.nlm.nih.gov/pubmed/6539790>
43. Sohaib SA, Koh DM, Barbachano Y, et al. Prospective assessment of MRI for imaging retroperitoneal metastases from testicular germ cell tumours. *Clin Radiol* 2009 Apr;64(4):362-7.
<http://www.ncbi.nlm.nih.gov/pubmed/19264179>

44. See WA, Hoxie L. Chest staging in testis cancer patients: imaging modality selection based upon risk assessment as determined by abdominal computerized tomography scan results. *J Urol* 1993 Sep;150(3):874-8.
<http://www.ncbi.nlm.nih.gov/pubmed/8345604>
45. de Wit M, Brenner W, Hartmann M, et al. [18F]-FDG-PET in clinical stage I/II non-seminomatous germ cell tumours: results of the German multicentre trial. *Ann Oncol* 2008 Sep;19(9):1619-23.
<http://www.ncbi.nlm.nih.gov/pubmed/18453520>
46. Huddart RA, O'Doherty MJ, Padhani A, et al. NCRI Testis Tumour Clinical Study Group. 18fluorodeoxyglucose positron emission tomography in the prediction of relapse in patients with highrisk, clinical stage I nonseminomatous germ cell tumors: preliminary report of MRC Trial TE22—the NCRI Testis Tumour Clinical Study Group. *J Clin Oncol* 2007 Jul;25(21):3090-5.
<http://www.ncbi.nlm.nih.gov/pubmed/17634488>
47. Cremerius U, Wildberger JE, Borchers H, et al. Does positron emission tomography using 18-fluoro-2-deoxyglucose improve clinical staging of testicular cancer?- Results of a study in 50 patients. *Urology* 1999 Nov;54(5):900-4.
<http://www.ncbi.nlm.nih.gov/pubmed/10565755>
48. Albers P, Bender H, Yilmaz H, et al. Positron emission tomography in the clinical staging of patients with Stage I and II testicular germ cell tumours. *Urology* 1999 Apr;53(4):808-11.
<http://www.ncbi.nlm.nih.gov/pubmed/10197862>
49. De Santis M, Becherer A, Bokemeyer C, et al. 2-18fluoro-deoxy-D-glucose positron emission tomography is a reliable predictor for viable tumor in postchemotherapy seminoma: an update of the prospective multicentric SEMPET trial. *J Clin Oncol* 2004 Mar;22(6):1034-9.
<http://www.ncbi.nlm.nih.gov/pubmed/15020605>
50. Spermon JR, De Geus-Oei LF, Kiemeneij LA, et al. The role of (18)fluoro-2-deoxyglucose positron emission tomography in initial staging and re-staging after chemotherapy for testicular germ cell tumours. *BJU Int* 2002 Apr;89(6):549-56.
<http://www.ncbi.nlm.nih.gov/pubmed/11942962>
51. Bachner M, Loriot Y, Gross-Goupil M, et al. 2-¹⁸F-fluoro-deoxy-D-glucose positron emission tomography (FDG-PET) for postchemotherapy seminoma residual lesions: a retrospective validation of the SEMPET trial. *Ann* 2012 Jan;23(1):59-64.
<http://www.ncbi.nlm.nih.gov/pubmed/21460378>
52. Oechsle K, Hartmann M, Brenner W, et al. German Multicenter Positron Emission Tomography Study Group. [18F]Fluorodeoxyglucose positron emission tomography in nonseminomatous germ cell tumors after chemotherapy: the German multicenter positron emission tomography study group. *J Clin Oncol* 2008 Dec;26(36):5930-5.
<http://www.ncbi.nlm.nih.gov/pubmed/19018083>
53. Hinz S, Schrader M, Kempkensteffen C, et al. The role of positron emission tomography in the evaluation of residual masses after chemotherapy for advanced stage seminoma. *J Urol* 2008 Mar;179(3):936-40;discussion 940.
<http://www.ncbi.nlm.nih.gov/pubmed/18207171>
54. Sobin LH, Gospodariwicz M, Wittekind C (eds). TNM classification of malignant tumors. UICC International Union Against Cancer, 7th edn. Wiley-Blackwell, 2009 Dec; pp 249-254.
<http://www.uicc.org/tnm/>
55. Klepp O, Flodgren P, Maartman-Moe H, et al. Early clinical stages (CS1, CS1Mk+ and CS2A) of nonseminomatous testis cancer. Value of preand postorchidectomy serum tumour marker information in prediction of retroperitoneal lymph node metastases. Swedish-Norwegian Testicular Cancer Project (SWENOTECA). *Ann Oncol* 1990 Jul;1(4):281-8.
<http://www.ncbi.nlm.nih.gov/pubmed/1702312>
56. Zagars GK. Management of stage I seminoma: radiotherapy, in Horwich A (ed.). *Testicular Cancer: Investigation and Management*. London: Chapman & Hall Medical, 1999, p. 99.
57. Heidenreich A, Moul JW. Contralateral testicular biopsy procedure in patients with unilateral testis cancer: is it indicated? *Sem Urol Oncol* 2002 Nov;20(4):234-8.
<http://www.ncbi.nlm.nih.gov/pubmed/12489055>
58. Germa-Lluch JR, Garcia del Muro X, Maroto P, et al. Spanish Germ-Cell Cancer Group (GG). Clinical pattern and therapeutic results achieved in 1490 patients with germ-cell tumours of the testis: the experience of the Spanish Germ-Cell Cancer Group (GG). *Eur Urol* 2002 Dec;42(6):553-62.
<http://www.ncbi.nlm.nih.gov/pubmed/12477650>
59. Moul JW. Timely diagnosis of testicular cancer. *Urol CLin North Am* 2007;34(2):109-17; abstract vii.
<http://www.ncbi.nlm.nih.gov/pubmed/17484916>

60. Richie JP, Birnholz J, Garnick MB. Ultrasonography as a diagnostic adjunct for the evaluation of masses in the scrotum. *Surg Gynecol Obstet* 1982 May;154(5):695-8.
<http://www.ncbi.nlm.nih.gov/pubmed/7071705>
61. Kim W, Rosen MA, Langer JE, et al. US-MR Imaging correlation in pathologic conditions of the scrotum. *Radiographics* 2007 Sep-Oct;27(5):1239-53.
<http://www.ncbi.nlm.nih.gov/pubmed/17848688>
62. Shaw J. Diagnosis and treatment of testicular cancer. *Am Fam Physician* 2008 Feb;77(4):469-74.
<http://www.ncbi.nlm.nih.gov/pubmed/18326165>
63. Angulo JC, Gonzalez J, Rodriguez N, et al. Clinicopathological study of regressed testicular tumors (apparent extragonadal germ cell neoplasms). *J Urol* 2009 Nov;182(5):2303-10.
<http://www.ncbi.nlm.nih.gov/pubmed/19762049>
64. Scholz M, Zehender M, Thalmann GN, et al. Extragenital retroperitoneal germ cell tumor: evidence of origin in testis. *Ann Oncol* 2002 Jan;13(1):121-4.
<http://www.ncbi.nlm.nih.gov/pubmed/11863093>
65. Mancini M, Carmignani L, Gazzano G, et al. High prevalence of testicular cancer in azoospermic men without spermatogenesis. *Hum Reprod* 2007 Apr; 22(4):1042-6.
<http://www.ncbi.nlm.nih.gov/pubmed/17220165>
66. Cassidy FH, Ishioka KM, McMahon CJ, et al. MR imaging of scrotal tumors and pseudotumors. *Radiographics* 2010 May;30(3):665-83.
<http://www.ncbi.nlm.nih.gov/pubmed/20462987>
67. Klein EA. Tumour markers in testis cancer. *Urol Clin North Am* 1993 Feb;20(1):67-73.
<http://www.ncbi.nlm.nih.gov/pubmed/7679533>
68. Javadpour N. The role of biologic markers in testicular cancer. *Cancer* 1980 Apr;45(7 Suppl): 1755-61. [No abstract available]
<http://www.ncbi.nlm.nih.gov/pubmed/6154517>
69. Koshida K, Uchibayashi T, Yamamoto H, et al. Significance of placental alkaline phosphatase (PLAP) in the monitoring of patients with seminoma. *Br J Urol* 1996 Jan;77(1):138-42.
<http://www.ncbi.nlm.nih.gov/pubmed/8653285>
70. Dieckmann KP, Loy V. Prevalence of contralateral testicular intraepithelial neoplasia in patients with testicular germ cell neoplasms. *J Clin Oncol* 1996 Dec;14(12):3126-32.
<http://www.ncbi.nlm.nih.gov/pubmed/8955658>
71. Von der Maase H, Rorth M, Walbom-Jorgensen S, et al. Carcinoma-in-situ of contralateral testis in patients with testicular germ cell cancer: study of 27 cases in 500 patients. *Br Med J (Clin Res Ed)* 1986 Nov;293(6559):1398-401.
<http://www.ncbi.nlm.nih.gov/pubmed/3026550>
72. Harland SJ, Cook PA, Fossa SD, et al. Intratubular germ cell neoplasia of contralateral testis in testicular cancer: defining a high risk group. *J Urol* 1998 Oct;160(4):1353-7.
<http://www.ncbi.nlm.nih.gov/pubmed/9751353>
73. Taberero J, Paz-Ares L, Salazar R, et al. Incidence of contralateral germ cell testicular tumours in South Europe: report of the experience at 2 Spanish university hospitals and review of the literature. *J Urol* 2004 Jan;171(1):164-7.
<http://www.ncbi.nlm.nih.gov/pubmed/14665868>
74. Herr HW, Sheinfeld J. Is biopsy of the contralateral testis necessary in patients with germ cell tumors? *J Urol* 1997 Oct;158(4):1331-4.
<http://www.ncbi.nlm.nih.gov/pubmed/9302113>
75. Albers P, Göll A, Bierhoff E, et al. Clinical course and histopathologic risk factor assessment in patients with bilateral testicular germ cell tumours. *Urology* 1999 Oct;54(4):714-8.
<http://www.ncbi.nlm.nih.gov/pubmed/10510934>
76. Giwercman A, Bruun E, Frimotd-Muller C, et al. Prevalence of carcinoma in situ and other histopathological abnormalities in testes of men with a history of cryptorchidism. *J Urol* 1989 Oct;142(4):998-1001.
<http://www.ncbi.nlm.nih.gov/pubmed/2571738>
77. Dieckmann KP, Kulejewski M, Pichlmeier U, et al. Diagnosis of contralateral testicular intraepithelial neoplasia (TIN) in patients with testicular germ cell cancer: systematic two-site biopsies are more sensitive than a single random biopsy. *Eur Urol* 2007 Jan;51(1):175-83;discussion 183-5.
<http://www.ncbi.nlm.nih.gov/pubmed/16814456>
78. Kliesch S, Thomaidis T, Schütte B, et al. Update on the diagnostic safety for detection of testicular intraepithelial neoplasia (TIN). *APMIS* 2003 Jan;111(1):70-4.
<http://www.ncbi.nlm.nih.gov/pubmed/12752238>

79. Classen J, Dieckmann K, Bamberg M, et al. German Testicular Cancer Study Group. Radiotherapy with 16 Gy may fail to eradicate testicular intraepithelial neoplasia: preliminary communication of a dose-reduction trial of the German Testicular Cancer Study Group. *Br J Cancer* 2003 Mar;88(6): 828-31.
<http://www.ncbi.nlm.nih.gov/pubmed/12644817>
80. Souchon R, Gertenbach U, Dieckmann KP, et al. Contralateral testicular cancer in spite of TINegative double biopsies and interval cisplatin chemotherapy. *J. Strahlenther Onkol* 2006 May;182(5):289-92.
<http://www.ncbi.nlm.nih.gov/pubmed/16673063>
81. Petersen PM, Giwercman A, Daugaard G, et al. Effect of graded testicular doses of radiotherapy in patients treated for carcinoma-in-situ in the testis. *J Clin Oncol* 2002 Aug;20(6):1537-43.
<http://www.ncbi.nlm.nih.gov/pubmed/11896102>
82. Heidenreich A, Hörtl W, Albrecht W, et al. Testis-preserving surgery in bilateral testicular germ cell tumours. *Br J Urol* 1997 Feb;79(2):253-7.
<http://www.ncbi.nlm.nih.gov/pubmed/9052478>
83. Høei-Hansen CE, Rajpert-De Meyts E, Daugaard G, et al. Carcinoma in situ testis, the progenitor of testicular germ cell tumours: a clinical review. *Ann Oncol* 2005 Jun;16(6):863-8.
<http://www.ncbi.nlm.nih.gov/pubmed/15821122>
84. Shelley MD, Burgon K, Mason MD. Treatment of testicular germ-cell cancer: a cochrane evidence-based systematic review. *Cancer Treat Rev* 2002 Oct;28(5):237-53.
<http://www.ncbi.nlm.nih.gov/pubmed/12435371>
85. Aparicio J, Germà JR, García del Muro X, et al. Second Spanish Germ Cell Cancer Cooperative Group. Risk-adapted management for patients with clinical stage I seminoma: the Second Spanish Germ Cell Cancer Cooperative Group study. *J Clin Oncol* 2005 Dec;23(34):8717-23.
<http://www.ncbi.nlm.nih.gov/pubmed/16260698>
86. Bokemeyer C, Schmoll HJ. Treatment of clinical stage I testicular cancer and a possible role for new biological prognostic parameters. *J Cancer Res Clin Oncol* 1996;122(10):575-84.
<http://www.ncbi.nlm.nih.gov/pubmed/8879254>
87. Albers P, Siener R, Kliesch S, et al. German Testicular Cancer Study Group. Risk factors for relapse in clinical stage I nonseminomatous testicular germ cell tumours: results of the German Testicular Cancer Study Group Trial. *J Clin Oncol* 2003 Apr;21(8):1505-12.
<http://www.ncbi.nlm.nih.gov/pubmed/12697874>
88. Alexandre J, Fizazi K, Mahe C, et al. Stage I non-seminomatous germ-cell tumours of the testis: identification of a subgroup of patients with a very low risk of relapse. *Eur J Cancer* 2001 Mar;37(5):576-82.
<http://www.ncbi.nlm.nih.gov/pubmed/11290432>
89. Petersen PM, Giwercman A, Skakkebaek NE, et al. Gonadal function in men with testicular cancer. *Semin Oncol* 1998 Apr;25(2):224-33.
<http://www.ncbi.nlm.nih.gov/pubmed/9562456>
90. De Santis M, Albrecht W, Hörtl W, et al. Impact of cytotoxic treatment on long-term fertility in patients with germ-cell cancer. *Int J Cancer* 1999 Dec;83(6):864-5.
<http://www.ncbi.nlm.nih.gov/pubmed/10597213>
91. Jacobsen KD, Fosså SD, Bjørø TP, et al. Gonadal function and fertility in patients with bilateral testicular germ cell malignancy. *Eur Urol* 2002 Sep;42(3):229-38.
<http://www.ncbi.nlm.nih.gov/pubmed/12234507>
92. Kliesch S, Behre HM, Jürgens H, et al. Cryopreservation of semen from adolescent patients with malignancies. *Med Pediatr Oncol* 1996 Jan;26(1):20-7.
<http://www.ncbi.nlm.nih.gov/pubmed/7494508>
93. Giwercman A, von der Maase H, Rørth M, et al. Semen quality in testicular tumour and CIS in the contralateral testis. *Lancet* 1993 Feb;341(8841):384-5. [No abstract available]
<http://www.ncbi.nlm.nih.gov/pubmed/8094162>
94. Kliesch S, Bergmann M, Hertle L, et al. Semen parameters and testicular pathology in men with testicular cancer and contralateral carcinoma in situ or bilateral testicular malignancies. *Hum Reprod* 1997 Dec;12(12):2830-5.
<http://www.ncbi.nlm.nih.gov/pubmed/9455863>
95. Spermon JR, Kiemeneij LA, Meuleman EJ, et al. Fertility in men with testicular germ cell tumours. *Fertil Steril* 2003 Jun;79(Suppl 3):1543-9.
<http://www.ncbi.nlm.nih.gov/pubmed/12801557>

96. Nieschlag E, Behre HM. Pharmacology and clinical use of testosterone, in Nieschlag E, Behre HM (eds). Testosterone-Action, Deficiency, Substitution. Berlin-Heidelberg-New York: Springer, 1999, pp. 92-114.
97. Skoogh J, Steineck G, Cavallin-Ståhl E, et al. on behalf of SWENOTECA. Feelings of loss and uneasiness or shame after removal of a testicle by orchidectomy: a population-based long-term follow-up of testicular cancer survivors. *Int J Androl* 2011 Apr;34(2):183-92.
<http://www.ncbi.nlm.nih.gov/pubmed/20550599>
98. Jungwirth A, Diemer T, Dohle GR, et al. EAU Guidelines on Male Infertility. Edn. presented at the EAU Annual Congress 2013. ISBN 978-90-79754-71-7. Arnhem, The Netherlands.
<http://www.uroweb.org/guidelines/online-guidelines/>
99. Groll RJ, Warde P, Jewett MA. A comprehensive systematic review of testicular germ cell tumor surveillance. *Crit Rev Oncol Hematol* 2007 Dec;64(3):182-97.
<http://www.ncbi.nlm.nih.gov/pubmed/17644403>
100. Aparicio J, García del Muro X, Maroto P, et al. Spanish Germ Cell Cancer Cooperative Group (GG). Multicenter study evaluating a dual policy of postorchidectomy surveillance and selective adjuvant single-agent carboplatin for patients with clinical stage I seminoma. *Ann Oncol* 2003 Jun;14(6): 867-72.
<http://www.ncbi.nlm.nih.gov/pubmed/12796024>
101. Aparicio J, Maroto P, Garcia del Muro X, et al. Prognostic factors for relapse in stage I seminoma: a new nomogram derived from three consecutive, risk-adapted studies from the Spanish Germ Cell Cancer Group (SGCCG). *Ann Oncol* 2014 Nov;25(11):2173-8.
<http://www.ncbi.nlm.nih.gov/pubmed/25210015>
102. Tandstad T, Smaaland R, Solberg A, et al. Management of Seminomatous Testicular Cancer: A Binational Prospective Population-Based Study From the Swedish Norwegian Testicular Cancer Study Group (SWENOTECA). *J Clin Oncol* 2011 Feb;29(6):719-25.
<http://www.ncbi.nlm.nih.gov/pubmed/21205748>
103. Oliver RT, Mead GM, Rustin GJ, et al. Randomized trial of carboplatin versus radiotherapy for stage I seminoma: mature results on relapse and contralateral testis cancer rates in MRC TE19/EORTC 30982 study (ISRCTN27163214). *J Clin Oncol* 2011 Mar;29(8):957-62.
<http://www.ncbi.nlm.nih.gov/pubmed/21282539>
104. Oliver RT, Mason MD, Mead GM, et al. MRC TE19 collaborators and the EORTC 30982 collaborators. Radiotherapy versus single-dose carboplatin in adjuvant treatment of stage I seminoma: a randomised trial. *Lancet* 2005 Jul;366(9482):293-300.
<http://www.ncbi.nlm.nih.gov/pubmed/16039331>
105. Mead GM, Fossa SD, Oliver RT, et al. MRC/EORTC seminoma trial collaborators. Randomized trials in 2466 patients with stage I seminoma: patterns of relapse and follow-up. *J Natl Cancer Inst* 2011 Feb;103(3):241-9.
<http://www.ncbi.nlm.nih.gov/pubmed/21212385>
106. Schoffski P, Höhn N, Kowalski R, et al. Health-related quality of life (QoL) in patients with seminoma stage I treated with either adjuvant radiotherapy (RT) or two cycles of carboplatinum chemotherapy (CT): Results of a randomized phase III trial of the German Interdisciplinary Working Party on Testicular Cancer. *ASCO Annual Meeting Proceedings. Part 1. J Clin Oncol* 2007;25(Suppl 18S):5050.
http://www.asco.org/ASCOv2/Meetings/Abstracts?vmview=abst_detail_view&confID=47&abstractID=32158
107. Fosså SD, Horwich A, Russell JM, et al. Optimal planning target volume for stage I testicular seminoma: A Medical Research Council Testicular Tumor Working Group randomized trial. *J Clin Oncol* 1999 Apr;17(4):1146.
<http://www.ncbi.nlm.nih.gov/pubmed/10561173>
108. Jones WG, Fossa SD, Mead GM, et al. A randomized trial of two radiotherapy schedules in the adjuvant treatment of stage I seminoma (MRC TE 18). *Eur J Cancer* 2001;37(Suppl 6):S157, abstr 572. [No abstract available]
[http://www.ejancer.com/article/S0959-8049\(01\)81064-9/abstract](http://www.ejancer.com/article/S0959-8049(01)81064-9/abstract)
109. Melchior D, Hammer P, Fimmers R, et al. Long term results and morbidity of paraaortic compared with paraaortic and iliac adjuvant radiation in clinical stage I seminoma. *Anticancer Res* 2001 Jul-Aug;21(4B):2989-93.
<http://www.ncbi.nlm.nih.gov/pubmed/11712799>
110. Livsey JE, Taylor B, Mobarek N, et al. Patterns of relapse following radiotherapy for stage I seminoma of the testis: implications for follow-up. *Clin Oncol (R Coll Radiol)* 2001;13(4):296-300.
<http://www.ncbi.nlm.nih.gov/pubmed/11554630>

111. Van Leeuwen FE, Stiggelbout AM, van den Belt-Dusebout AW, et al. Second cancer risk following testicular cancer: a follow-up study of 1,909 patients. *Clin Oncol* 1993 Mar;11(3):415-24. <http://www.ncbi.nlm.nih.gov/pubmed/8445415>
112. Travis LB, Curtis RE, Storm H, et al. Risk of second malignant neoplasms among long-term survivors of testicular cancer. *J Natl Cancer Inst* 1997 Oct;89(19):1429-39. <http://www.ncbi.nlm.nih.gov/pubmed/9326912>
113. Robinson D, Møller H, Horwich A. Mortality and incidence of second cancers following treatment for testicular cancer. *Br J Cancer* 2007 Feb;96(3):529-33. <http://www.ncbi.nlm.nih.gov/pubmed/17262080>
114. Bieri S, Rouzaud M, Miralbell R. Seminoma of the testis: is scrotal shielding necessary when radiotherapy is limited to the para-aortic nodes? *Radiother Oncol* 1999 Mar;50(3):349-53. <http://www.ncbi.nlm.nih.gov/pubmed/10392822>
115. van den Belt-Dusebout AW, de Wit R, Gietema JA, et al. Treatment-specific risks of second malignancies and cardiovascular disease in 5-year survivors of testicular cancer. *J Clin Oncol* 2007 Oct;25(28):4370-8. <http://www.ncbi.nlm.nih.gov/pubmed/17906202>
116. Horwich A, Fossa SD, Huddart R, et al. Second cancer risk and mortality in men treated with radiotherapy for stage I seminoma. *Br J Cancer* 2014 Jan 7;110(1):256-63. <http://www.ncbi.nlm.nih.gov/pubmed/24263066>
117. Aparicio J, Maroto P, del Muro XG, et al. Risk-adapted treatment in clinical stage I testicular seminoma: the third Spanish Germ Cell Cancer Group study. *J Clin Oncol* 2011 Dec;29(35):4677-81. <http://www.ncbi.nlm.nih.gov/pubmed/22042940>
118. Freedman LS, Parkinson MC, Jones WG, et al. Histopathology in the prediction of relapse of patients with stage I testicular teratoma treated by orchidectomy alone. *Lancet* 1987 Aug;2(8554):294-8. <http://www.ncbi.nlm.nih.gov/pubmed/2886764>
119. Read G, Stenning SP, Cullen MH, et al. Medical Research Council prospective study of surveillance for stage I testicular teratoma. *J Clin Oncol* 1992 Nov;10(11):1762-8. <http://www.ncbi.nlm.nih.gov/pubmed/1403057>
120. Colls BM, Harvey VJ, Skelton L, et al. Late results of surveillance of clinical stage I nonseminoma germ cell testicular tumours: 17 years' experience in a national study in New Zealand. *Br J Urol Int* 1999 Jan;83(1):76-82. <http://www.ncbi.nlm.nih.gov/pubmed/10233456>
121. Oliver RT, Ong J, Shamash J, et al. Anglian Germ Cell Cancer Group. Long-term follow-up of Anglian Germ Cell Cancer Group surveillance versus patients with Stage 1 nonseminoma treated with adjuvant chemotherapy. *Urology* 2004 Mar;63(3):556-61. <http://www.ncbi.nlm.nih.gov/pubmed/15028457>
1227. Zuniga A, Kakiashvili D, Jewett MA. Surveillance in stage I nonseminomatous germ cell tumours of the testis. *BJU Int* 2009 Nov;104(9 Pt B):1351-6. [No abstract available] <http://www.ncbi.nlm.nih.gov/pubmed/19840012>
123. Klepp O, Olsson AM, Henrikson H, et al. Prognostic factors in clinical stage I nonseminomatous germ cell tumours of the testis: multivariate analysis of a prospective multicenter study. *J Clin Oncol* 1990 Mar;8(3):509-18. <http://www.ncbi.nlm.nih.gov/pubmed/1689773>
124. Kakiashvili D, Anson-Cartwright L, Sturgeon JF, et al. Non risk-adapted surveillance management for clinical stage I nonseminomatous testis tumors. *J Urol* 2007;177:278 (abstr #835). <http://www.ncbi.nlm.nih.gov/pubmed/21190791>
125. Kollmannsberger C, Moore C, Chi KN, et al. Non-risk-adapted surveillance for patients with stage I nonseminomatous testicular germ-cell tumors: diminishing treatment-related morbidity while maintaining efficacy. *Ann Oncol* 2010 Jun;21(6):1296-301. <http://www.ncbi.nlm.nih.gov/pubmed/19875756>
126. Nichols CR, Roth B, Albers P, et al. Active surveillance is the preferred approach to clinical stage I testicular cancer. *J Clin* 2013 Oct;31(28):3490-3. <http://www.ncbi.nlm.nih.gov/pubmed/24002502>
127. Cullen MH, Stenning SP, Parkinson MC, et al. Short-course adjuvant chemotherapy in high-risk stage I nonseminomatous germ cell tumors of the testis: a Medical Research Council report. *J Clin Oncol* 1996 Apr;14(4):1106-13. <http://www.ncbi.nlm.nih.gov/pubmed/8648364>

128. Oliver RT, Raja MA, Ong J, et al. Pilot study to evaluate impact of a policy of adjuvant chemotherapy for high risk stage I malignant teratoma on overall relapse rate of stage I cancer patients. *J Urol* 1992 Nov;148(5):1453-6.
<http://www.ncbi.nlm.nih.gov/pubmed/1279211>
129. Studer UE, Fey MF, Calderoni A, et al. Adjuvant chemotherapy after orchidectomy in high-risk patients with clinical stage I nonseminomatous testicular cancer. *Eur Urol* 1993;23(4):444-9.
<http://www.ncbi.nlm.nih.gov/pubmed/7687549>
130. Böhlen D, Borner M, Sonntag RW, et al. Long-term results following adjuvant chemotherapy in patients with clinical stage I testicular nonseminomatous malignant germ cell tumors with high risk factors. *J Urol* 1999 Apr;161(4):1148-52.
<http://www.ncbi.nlm.nih.gov/pubmed/10081858>
131. Pont J, Albrecht W, Postner G, et al. Adjuvant chemotherapy for high-risk clinical stage I nonseminomatous testicular germ cell cancer: long-term results of a prospective trial. *J Clin Oncol* 1996 Feb;14(2):441-8.
<http://www.ncbi.nlm.nih.gov/pubmed/8636755>
132. Chevreau C, Mazerolles C, Soulié M, et al. Long-term efficacy of two cycles of BEP regimen in highrisk stage I nonseminomatous testicular germ cell tumors with embryonal carcinoma and/or vascular invasion. *Eur Urol* 2004 Aug;46(2):209-14.
<http://www.ncbi.nlm.nih.gov/pubmed/15245815>
133. Böhlen D, Burkhard FC, Mills R, et al. Fertility and sexual function following orchidectomy and 2 cycles of chemotherapy for stage I high risk nonseminomatous germ cell cancer. *J Urol* 2001 Feb;165(2):441-4.
<http://www.ncbi.nlm.nih.gov/pubmed/11176393>
134. Huddart RA, Norman A, Shahidi M, et al. Cardiovascular disease as a long-term complication of treatment for testicular cancer. *J Clin Oncol* 2003 Apr;21(8):1513-23.
<http://www.ncbi.nlm.nih.gov/pubmed/12697875>
135. Albers P, Siener R, Krege S, et al. German Testicular Cancer Study Group. Randomized phase III trial comparing retroperitoneal lymph node dissection with one course of bleomycin and etoposide plus cisplatin chemotherapy in the adjuvant treatment of clinical stage I Nonseminomatous testicular germ cell tumors: AUO trial AH 01/94 by the German Testicular Cancer Study Group. *J Clin Oncol* 2008 Jun; 26(18):2966-72.
<http://www.ncbi.nlm.nih.gov/pubmed/18458040>
136. Tandstad T, Dahl O, Cohn-Cedermark G, et al. Risk-adapted treatment in clinical stage I nonseminomatous germ cell testicular cancer: the SWENOTECA management program. *J Clin Oncol* 2009 May;27(13):2122-8.
<http://www.ncbi.nlm.nih.gov/pubmed/19307506>
137. Tandstad T, Stahl O, Hakansson U, et al. One course of adjuvant BEP in clinical stage I nonseminoma mature and expanded results from the SWENOTECA group. *Ann* 2014 Nov;25(11):2567-72.
<http://www.ncbi.nlm.nih.gov/pubmed/25114021>
138. Baniel J, Foster RS, Gonin R, et al. Late relapse of testicular cancer. *J Clin Oncol* 1995 May;13(5):1170-6.
<http://www.ncbi.nlm.nih.gov/pubmed/7537800>
139. Westermann DH, Schefer H, Thalmann GN, et al. Long-term followup results of 1 cycle of adjuvant bleomycin, etoposide and cisplatin chemotherapy for high risk clinical stage I nonseminomatous germ cell tumors of the testis. *J Urol* 2008 Jan;179(1):163-6.
<http://www.ncbi.nlm.nih.gov/pubmed/18001800>
140. Baniel J, Roth BJ, Foster RS, et al. Cost- and risk-benefit considerations in the management of clinical stage I nonseminomatous testicular tumors. *Ann Surg Oncol* 1996 Jan;3(1):86-93.
<http://www.ncbi.nlm.nih.gov/pubmed/8770308>
141. Rustin GJ, Mead GM, Stenning SP, et al. National Cancer Research Institute Testis Cancer Clinical Studies Group. Randomized trial of two or five computed tomography scans in the surveillance of patients with stage I nonseminomatous germ cell tumors of the testis: Medical Research Council Trial TE08, ISRCTN56475197-the National Cancer Research Institute Testis Cancer Clinical Studies Group. *J Clin Oncol* 2007 Apr;25(11):1310-5.
<http://www.ncbi.nlm.nih.gov/pubmed/17416851>
142. Klepp O, Dahl O, Flodgren P et al. Riskadapted treatment of clinical stage 1 non-seminoma testis cancer. *Eur J Cancer* 1997 Jun;33(7):1038-44.
<http://www.ncbi.nlm.nih.gov/pubmed/9376184>

143. Ondrus D, Matoska J, Belan V, et al. Prognostic factors in clinical stage I nonseminomatous germ cell testicular tumors: rationale for different risk-adapted treatment. *Eur Urol* 1998;33(6):562-6.
<http://www.ncbi.nlm.nih.gov/pubmed/9743698>
144. Maroto P, García del Muro X, Aparicio J, et al. Multicentre risk-adapted management for stage I nonseminomatous germ cell tumours. *Ann Oncol* 2005 Dec;16(12):1915-20.
<http://www.ncbi.nlm.nih.gov/pubmed/16126737>
145. Tandstad T, Cohn-Cedermark G, Dahl O, et al. Long-term follow-up after risk-adapted treatment in clinical stage 1 (CS1) nonseminomatous germ-cell testicular cancer (NSGCT) implementing adjuvant CVB chemotherapy. A SWENOTECA study. *Ann Oncol* 2010 Sep;21(9):1858-63.
<http://www.ncbi.nlm.nih.gov/pubmed/20142410>
146. Heidenreich A, Albers P, Hartmann M, et al. German Testicular Cancer Study Group. Complications of primary nerve sparing retroperitoneal lymph node dissection for clinical stage I nonseminomatous germ cell tumours of the testis: experience of the German Testicular Cancer Study Group. *J Urol* 2003 May;169(5):1710-4.
<http://www.ncbi.nlm.nih.gov/pubmed/12686815>
147. Spermon JR, Roeleveld TA, van der Poel HG, et al. Comparison of surveillance and retroperitoneal lymph node dissection in stage I nonseminomatous germ cell tumors. *Urology* 2002 Jun;59(6):923-9.
<http://www.ncbi.nlm.nih.gov/pubmed/12031382>
148. Hendry WF, Norman A, Nicholls J, et al. Abdominal relapse in Stage 1 nonseminomatous germ cell tumours of the testis managed by surveillance or with adjuvant chemotherapy. *BJU Int* 2000 Jul;86(1):89-93.
<http://www.ncbi.nlm.nih.gov/pubmed/10886090>
149. Nicolai N, Miceli R, Necchi A, et al. Retroperitoneal lymph node dissection with no adjuvant chemotherapy in clinical stage I nonseminomatous germ cell tumours: long-term outcome and analysis of risk factors of recurrence. *Eur Urol* 2010 Dec;58(6):912-8.
<http://www.ncbi.nlm.nih.gov/pubmed/20817343>
150. Donohue JP, Thornhill JA, Foster RS, et al. Retroperitoneal lymphadenectomy for clinical stage A testis cancer (1965 to 1989): modifications of technique and impact on ejaculation. *J Urol* 1993 Feb;149(2):237-43.
<http://www.ncbi.nlm.nih.gov/pubmed/8381190>
151. Al-Ahmadie HA, Carver BS, Cronin AM, et al. Primary retroperitoneal lymph node dissection in low-stage testicular germ cell tumors: a detailed pathologic study with clinical outcome analysis with special emphasis on patients who did not receive adjuvant therapy. *Urology* 2013 Dec;82(6):1341-6.
<http://www.ncbi.nlm.nih.gov/pubmed/24094656>
152. Foster RS, Roth BJ. Clinical stage I nonseminoma: surgery versus surveillance. *Semin Oncol* 1998 Apr;25(2):145-53.
<http://www.ncbi.nlm.nih.gov/pubmed/9562447>
153. Rassweiler JJ, Scheitlin W, Heidenreich A, Laguna MP, Janetschek G. Laparoscopic retroperitoneal lymph node dissection: does it still have a role in the management of clinical stage I nonseminomatous testis cancer? A European perspective. *Eur Urol* 2008 Nov;54(5):1004-15.
<http://www.ncbi.nlm.nih.gov/pubmed/18722704>
154. Neyer M, Peschel R, Akkad T, Springer-Stohr B, Berger A, Bartsch G, Steiner H. Long-term results of laparoscopic retroperitoneal lymph-node dissection for clinical stage I nonseminomatous germ-cell testicular cancer. *J Endourol* 2007 Feb;21(2):180-3.
<http://www.ncbi.nlm.nih.gov/pubmed/17338618>
155. Krega S, Beyer J, Souchon R, et al. European consensus conference on diagnosis and treatment of germ cell cancer: a report of the second meeting of the European Germ Cell Cancer Consensus Group (EGCCCG): part II. *Eur Urol* 2008 Mar;53(3):497-513.
<http://www.ncbi.nlm.nih.gov/pubmed/18191015>
156. Pizzocaro G, Nicolai N, Salvioni R. Marker positive clinical stage I non seminomatous germ cell tumours (NSGCT) of the testis: which primary therapy? *J Urol* 1996;155(Suppl):328A.
157. Davis BE, Herr HW, Fair WR, et al. The management of patients with nonseminomatous germ cell tumors of the testis with serologic disease only after orchidectomy. *J Urol* 1994 Jul;152(1):111-3.
<http://www.ncbi.nlm.nih.gov/pubmed/7515445>
158. Classen J, Schmidberger H, Meisner C, et al. Radiotherapy for stages IIA/B testicular seminoma: final report of a prospective multicenter clinical trial. *J Clin Oncol* 2003 Mar;21(6):1101-6.
<http://www.ncbi.nlm.nih.gov/pubmed/12637477>

159. Chung PW, Gospodarowicz MK, Panzarella T, et al. Stage II testicular seminoma: patterns of recurrence and outcome of treatment. *Eur Urol* 2004 Jun;45(6):754-59;discussion 759-60.
<http://www.ncbi.nlm.nih.gov/pubmed/15149748>
160. Weissbach L. Guidelines for the diagnosis and therapy of testicular cancer and new developments. *Urol Int* 1999;63(1):46-56.
<http://www.ncbi.nlm.nih.gov/pubmed/10592490>
161. Horwich A, Dearnaley DP, Sohaib A, et al. Neoadjuvant carboplatin before radiotherapy in stage IIA and IIB seminoma. *Ann Oncol* 2013 Aug;24(8):2104-7.
<http://www.ncbi.nlm.nih.gov/pubmed/23592702>
162. Garcia-del-Muro X, Maroto P, Gumà J, et al. Chemotherapy as an alternative to radiotherapy in the treatment of stage IIA and IIB testicular seminoma: a Spanish Germ Cell Cancer Group Study. *J Clin Oncol* 2008 Nov;26(33):5416-21.
<http://www.ncbi.nlm.nih.gov/pubmed/18936476>
163. Krege S, Boergermann C, Baschek R, et al. German Testicular Cancer Study Group (GTCSG). Single agent carboplatin for CS IIA/B testicular seminoma. A phase II study of the German Testicular Cancer Study Group (GTCSG). *Ann Oncol* 2006 Feb;17(2):276-80.
<http://www.ncbi.nlm.nih.gov/pubmed/16254023>
164. Stephenson AJ, Bosl GJ, Motzer RJ, et al. Nonrandomized comparison of primary chemotherapy and retroperitoneal lymph node dissection for clinical stage IIA and IIB nonseminomatous germ cell testicular cancer. *J Clin* 2007 Dec 10;25(35):5597-602.
<http://www.ncbi.nlm.nih.gov/pubmed/18065732>
165. Frohlich MW, Small EJ. Stage II nonseminomatous testis cancer: the roles of primary and adjuvant chemotherapy. *Urol Clin North Am* 1998 Aug;25(3):451-9.
<http://www.ncbi.nlm.nih.gov/pubmed/9728214>
166. Peckham MJ, Hendry WF. Clinical stage II non-seminatous germ cell testicular tumors. Results of management by primary chemotherapy. *Br J Urol* 1985 Dec;57(6):763-8.
<http://www.ncbi.nlm.nih.gov/pubmed/2417652>
167. Logothetis CJ, Samuels ML, Selig DE, et al. Primary chemotherapy followed by a selective retroperitoneal lymphadenectomy in the management of clinical stage II testicular carcinoma: a preliminary report. *J Urol* 1985 Dec;134(6):1127-30.
<http://www.ncbi.nlm.nih.gov/pubmed/2414470>
168. Horwich A, Stenning S. Initial chemotherapy for stage II testicular non-seminoma. *World J Urol* 1994;12(3):148-50.
<http://www.ncbi.nlm.nih.gov/pubmed/7951341>
169. Weissbach L, Bussar-Maatz R, Fletchner H, et al. RPLND or primary chemotherapy in clinical stage IIA/B nonseminomatous germ cell tumors. Results of a prospective multicenter trial including quality of life assessment. *Eur Urol* 2000 May;37(5):582-94.
<http://www.ncbi.nlm.nih.gov/pubmed/10765098>
170. Williams SD, Stablein DM, Einhorn LH, et al. Immediate adjuvant chemotherapy versus observation with treatment at relapse in pathological stage II testicular cancer. *N Engl J Med* 1987 Dec;317(23):1433-8.
<http://www.ncbi.nlm.nih.gov/pubmed/2446132>
171. Sternberg CN. Role of primary chemotherapy in stage I and low-volume stage II nonseminomatous germ-cell testis tumors. *Urol Clin North Am* 1993 Feb;20(1):93-109.
<http://www.ncbi.nlm.nih.gov/pubmed/8382000>
172. Horwich A, Norman A, Fisher C, et al. Primary chemotherapy for stage II nonseminomatous germ cell tumors of the testis. *J Urol* 1994 Jan;151(1):72-7.
<http://www.ncbi.nlm.nih.gov/pubmed/8254836>
173. Donohue JP, Thornhill JA, Foster RS, et al. The role of retroperitoneal lymphadenectomy in clinical stage B testis cancer: the Indiana University Experience (1965 to 1989). *J Urol* 1995 Jan;153(1):85-9.
<http://www.ncbi.nlm.nih.gov/pubmed/7966799>
174. Motzer RJ, Sheinfeld J, Mazumdar M, et al. Etoposide and cisplatin adjuvant therapy for patients with pathological stage II germ cell tumors. *J Clin Oncol* 1995 Nov;13(11):2700-4.
<http://www.ncbi.nlm.nih.gov/pubmed/7595727>
175. Hartlapp JH, Weissbach L, Bussar-Maatz R. Adjuvant chemotherapy in nonseminomatous testicular tumour stage II. *Int J Androl* 1987 Feb;10(1):277-84.
<http://www.ncbi.nlm.nih.gov/pubmed/2438221>

176. Logothetis CJ, Swanson DA, Dexeus F, et al. Primary chemotherapy for clinical stage II nonseminomatous germ cell tumors of the testis: a follow-up of 50 patients. *J Clin Oncol* 1987 Jun;5(6):906-11.
<http://www.ncbi.nlm.nih.gov/pubmed/2438389>
177. Bokemeyer C, Kollmannsberger C, Stenning S, et al. Metastatic seminoma treated with either single agent carboplatin or cisplatin-based combination chemotherapy: a pooled analysis of two randomised trials. *Br J Cancer* 2004 Aug 16;91(4):683-7.
<http://www.ncbi.nlm.nih.gov/pubmed/15266338>
178. Fizazi K, Delva R, Caty A, et al. A risk-adapted study of cisplatin and etoposide, with or without ifosfamide, in patients with metastatic seminoma: results of the GETUG S99 multicenter prospective study. *Eur Urol* 2014 Feb;65(2):381-6.
<http://www.ncbi.nlm.nih.gov/pubmed/24094847>
179. de Wit R. Refining the optimal chemotherapy regimen in good prognosis germ cell cancer: interpretation of the current body of knowledge. *J Clin* 2007 Oct 1;25(28):4346-9.
<http://www.ncbi.nlm.nih.gov/pubmed/17906198>
180. Beyer J, Bokemeyer C. [Chemotherapy for germ cell cancer]. *Urologe A* 2004 Dec;43(12):1507-13. [Article in German].
<http://www.ncbi.nlm.nih.gov/pubmed/15592707>
181. Saxman SB, Finch D, Gonin R, et al. Long-term follow-up of a phase III study of three versus four cycles of bleomycin, etoposide and cisplatin in favorable-prognosis germ-cell tumors: the Indiana University Experience. *J Clin Oncol* 1998 Feb;16(2):702-6.
<http://www.ncbi.nlm.nih.gov/pubmed/9469360>
182. de Wit R, Stoter G, Kaye SB, et al. Importance of bleomycin in combination chemotherapy for good-prognosis testicular nonseminoma: a randomized study of the European Organization for Research and Treatment of Cancer Genitourinary Tract Cancer Cooperative Group. *J Clin Oncol* 1997 May;15(5):1837-43.
<http://www.ncbi.nlm.nih.gov/pubmed/9164193>
183. Horwich A, Sleijfer DT, Fosså SD, et al. Randomized trial of bleomycin, etoposide and cisplatin compared with bleomycin, etoposide and carboplatin in good-prognosis metastatic nonseminomatous germ cell cancer: a Multiinstitutional Medical Research Council/European Organization for Research and Treatment of Cancer trial. *J Clin Oncol* 1997 May;15(5):1844-52.
<http://www.ncbi.nlm.nih.gov/pubmed/9164194>
184. De Wit R, Roberts JT, Wilkinson PM, et al. Equivalence of three or four cycles of bleomycin, etoposide, and cisplatin chemotherapy and of a 3- or 5- day schedule in good-prognosis germ cell cancer: a randomized study of the European Organization for Research and Treatment of Cancer Genitourinary Tract Cancer Cooperative Group and the Medical research Council. *J Clin Oncol* 2001 Mar;19(6):1629-40.
<http://www.ncbi.nlm.nih.gov/pubmed/11250991>
185. Bokemeyer C, Kuczyk MA, Köhne H, et al. Hematopoietic growth factors and treatment of testicular cancer: biological interactions, routine use and dose-intensive chemotherapy. *Ann Hematol* 1996 Jan;72(1):1-9.
<http://www.ncbi.nlm.nih.gov/pubmed/8605273>
186. Xiao H, Mazumdar M, Bajorin DF, et al. Longterm follow-up of patients with good-risk germ cell tumors treated with etoposide and cisplatin. *J Clin Oncol* 1997 Jul;15(7):2553-8.
<http://www.ncbi.nlm.nih.gov/pubmed/9215824>
187. Culine S, Kerbrat P, Kramar A, et al. Genito-Urinary Group of the French Federation of Cancer Center (GETUG T93BP). Refining the optimal chemotherapy regimen for good-risk metastatic nonseminomatous germ-cell tumors: a randomized trial of the Genito-Urinary Group of the French Federation of Cancer Centers (GETUG T93BP). *Ann Oncol* 2007 May;18(5):917-24.
<http://www.ncbi.nlm.nih.gov/pubmed/17351252>
188. Grimison PS, Stockler MR, Thomson DB, et al. J Natl Cancer Inst 2010. Comparison of two standard chemotherapy regimens for good-prognosis germ cell tumors: updated analysis of a randomized trial. *J Natl Cancer Inst.* 2010 Aug;102(16):1253-62.
<http://www.ncbi.nlm.nih.gov/pubmed/20631341>
189. Fosså SD, Kaye SB, Mead GM, et al. Filgrastim during combination chemotherapy of patients with poor prognosis metastatic germ cell malignancy. European Organization for Research and Treatment of Cancer, Genito-Urinary Group, and the Medical Research Council Testicular Cancer Working Party, Cambridge, United Kingdom. *J Clin Oncol* 1998 Feb;16(2):716-24.
<http://www.ncbi.nlm.nih.gov/pubmed/9469362>

190. De Wit R, Stoter G, Sleijfer DT, et al. Four cycles of BEP vs four cycles of VIP in patients with intermediate-prognosis metastatic testicular non-seminoma: a randomized study of the EORTC Genitourinary Tract Cancer Cooperative Group. European Organization for Research and Treatment of Cancer. *Br J Cancer* 1998 Sep;78(6):828-32.
<http://www.ncbi.nlm.nih.gov/pubmed/9743309>
191. de Wit R, Skoneczna I, Daugaard G, et al. Randomized phase III study comparing paclitaxel-bleomycin, etoposide, and cisplatin (BEP) to standard BEP in intermediate-prognosis germ-cell cancer: intergroup study EORTC 30983. *J Clin Oncol* 2012 Mar 10;30(8):792-9.
<http://www.ncbi.nlm.nih.gov/pubmed/22271474>
192. De Wit R, Louwerens M, de Mulder PH, et al. Management of intermediate-prognosis germ-cell cancer: results of a phase I/II study of Taxol-BEP. *Int J Cancer* 1999 Dec;83(6):831-3.
<http://www.ncbi.nlm.nih.gov/pubmed/10597204>
193. Nichols CR, Catalano PJ, Crawford ED, et al. Randomized comparison of cisplatin and etoposide and either bleomycin or ifosfamide in treatment of advanced disseminated germ cell tumors: an Eastern Cooperative Oncology Group, Southwest Oncology Group, and Cancer and Leukemia Group B Study. *J Clin Oncol* 1998 Apr;16(4):1287-93.
<http://www.ncbi.nlm.nih.gov/pubmed/9552027>
194. Motzer RJ, Nichols CJ, Margolin KA, et al. Phase III randomized trial of conventional-dose chemotherapy with or without high-dose chemotherapy and autologous hematopoietic stem-cell rescue as first-line treatment for patients with poor-prognosis metastatic germ cell tumors. *J Clin Oncol* 2007 Jan;25(3):247-56.
<http://www.ncbi.nlm.nih.gov/pubmed/17235042>
195. Droz JP, Kramar A, Biron P, et al. Genito-Urinary Group of the French Federation of Cancer Centers (GETUG). Failure of high-dose cyclophosphamide and etoposide combined with double-dose cisplatin and bone marrow support in patients with high-volume metastatic nonseminomatous germ-cell tumours: mature results of a randomised trial. *Eur Urol* 2007 Mar;51(3):739-46;discussion 747-8.
<http://www.ncbi.nlm.nih.gov/pubmed/17084512>
196. Daugaard G, Skoneczna I, Aass N, et al. A randomized phase III study comparing standard dose BEP with sequential high-dose cisplatin, etoposide, and ifosfamide (VIP) plus stem-cell support in males with poor-prognosis germ-cell cancer. An intergroup study of EORTC, GTCSG, and Grupo Germinal (EORTC 30974). *Ann Oncol* 2011 May;22(5):1054-61.
<http://www.ncbi.nlm.nih.gov/pubmed/21059637>
197. Olofsson SE, Tandstad T, Jerkeman M, et al. Population-based study of treatment guided by tumor marker decline in patients with metastatic nonseminomatous germ cell tumor: a report from the Swedish-Norwegian Testicular Cancer Group. *J Clin Oncol* 2011 May 20;29(15):2032-9.
<http://www.ncbi.nlm.nih.gov/pubmed/21482994>
198. Motzer RJ, Mazumdar M, Bajorin DF, et al. High-dose carboplatin, etoposide, and cyclophosphamide with autologous bone marrow transplantation in first-line therapy for patients with poor-risk germ cell tumors. *J Clin Oncol* 1997 Jul;15(7):2546-52.
<http://www.ncbi.nlm.nih.gov/pubmed/9215823>
199. Bokemeyer C, Kollmannsberger C, Meisner C, et al. First-line high-dose chemotherapy compared with standard-dose PEB/VIP chemotherapy in patients with advanced germ cell tumors: a multivariate and matched-pair analysis. *J Clin Oncol* 1999 Nov;17(11):3450-6.
<http://www.ncbi.nlm.nih.gov/pubmed/10550141>
200. Thibault C, Fizazi K, Barrios D, et al. Compliance with guidelines and correlation with outcome in patients with advanced germ-cell tumours. *Eur J Cancer* 2014 May;50(7):1284-90.
<http://www.ncbi.nlm.nih.gov/pubmed/24560488>
201. Massard C, Plantade A, Gross-Goupil M, et al. Poor prognosis nonseminomatous germ-cell tumours (NSGCTs): should chemotherapy doses be reduced at first cycle to prevent acute respiratory distress syndrome in patients with multiple lung metastases? *Ann Oncol* 2010 Aug;21(8):1585-8.
<http://www.ncbi.nlm.nih.gov/pubmed/20181575>
202. Gillissen S, Powles T, Lim L, et al. Low-dose induction chemotherapy with Baby-BOP in patients with metastatic germ-cell tumours does not compromise outcome: a single-centre experience. *Ann Oncol* 2010 Aug;21(8):1589-93.
<http://www.ncbi.nlm.nih.gov/pubmed/20164149>
203. Gerl A, Clemm C, Lamerz R, et al. Prognostic implications of tumour marker analysis in nonseminomatous germ cell tumours with poor prognosis metastatic disease. *Eur J Cancer* 1993;29A(7):961-5.
<http://www.ncbi.nlm.nih.gov/pubmed/7684597>

204. Murphy BA, Motzer RJ, Mazumdar M, et al. Serum tumour marker decline is an early predictor of treatment outcome in germ cell tumour patients treated with cisplatin and ifosfamide salvage chemotherapy. *Cancer* 1994 May;73(10):2520-6.
<http://www.ncbi.nlm.nih.gov/pubmed/7513603>
205. André F, Fizazi K, Culine S, et al. The growing teratoma syndrome: results of therapy and long-term follow-up of 33 patients. *Eur J Cancer* 2000 Jul;36(11):1389-94.
<http://www.ncbi.nlm.nih.gov/pubmed/10899652>
206. De Wit R, Collette L, Sylvester R, et al. Serum alpha-fetoprotein surge after the initiation of chemotherapy for non-seminomatous testicular cancer has an adverse prognostic significance. *Br J Cancer* 1998 Nov;78(10):1350-5.
<http://www.ncbi.nlm.nih.gov/pubmed/9823978>
207. Zon RT, Nichols C, Einhorn LH. Management strategies and outcomes of germ cell tumour patients with very high human chorionic gonadotropin levels. *J Clin Oncol* 1998 Apr;16(4):1294-7.
<http://www.ncbi.nlm.nih.gov/pubmed/9552028>
208. Fosså SD, Stenning SP, Gerl A, et al. Prognostic factors in patients progressing after cisplatin-based chemotherapy for malignant non-seminomatous germ cell tumours. *Br J Cancer* 1999 Jul;80(9):1392-9.
<http://www.ncbi.nlm.nih.gov/pubmed/10424741>
209. Herr HW, Bosl G. Residual mass after after chemotherapy for seminoma: changing concepts of management. *J Urol* 1987 Jun;137(6):1234-5.
<http://www.ncbi.nlm.nih.gov/pubmed/2438431>
210. Hofmockel G, Gruss A, Theiss M. Chemotherapy in advanced seminoma and the role of postcytostatic retroperitoneal lymph node dissection. *Urol Int* 1996;57(1):38-42.
<http://www.ncbi.nlm.nih.gov/pubmed/8840489>
211. Kamat MR, Kulkarni JN, Tongoankar HB, et al. Value of retroperitoneal lymph node dissection in advanced testicular seminoma. *J Surg Oncol* 1992 Sep;51(1):65-7.
<http://www.ncbi.nlm.nih.gov/pubmed/1381455>
212. Loehrer PJ Sr, Birch R, Williams SD, et al. Chemotherapy of metastatic seminoma: the SoutheasternCancer Study Group experience. *J Clin Oncol* 1987 Aug;5(8):1212-20.
<http://www.ncbi.nlm.nih.gov/pubmed/2442317>
213. Motzer R, Bosl G, Heelan R, et al. Residual mass: an indication for further therapy in patients with advanced seminoma following systemic chemotherapy. *J Clin Oncol* 1987 Jul;5(7):1064-70.
<http://www.ncbi.nlm.nih.gov/pubmed/3598610>
214. Peckham MJ, Horwich A, Hendry WF. Advanced seminoma treatment with cisplatin based combination chemotherapy or carboplatin (JM8). *Br J Cancer* 1985 Jul;52(1):7-13.
<http://www.ncbi.nlm.nih.gov/pubmed/3893507>
215. Fosså SD, Borge L, Aass N, et al. The treatment of advanced metastatic seminoma: experience in 55 cases. *J Clin Oncol* 1987 Jul;5(7):1071-7.
<http://www.ncbi.nlm.nih.gov/pubmed/2439660>
216. Bamberg M, Classen J. [Value of radiotherapy of residual tumors after chemotherapy of metastatic seminomas] *Strahlenther Onkol* 1998 Aug;174(8):442-3. [Article in German] [No abstract available]
<http://www.ncbi.nlm.nih.gov/pubmed/9739390>
217. Duchesne GM, Stenning SP, Aass N, et al. Radiotherapy after chemotherapy for metastatic seminoma -a diminishing role. MRC Testicular Tumour Working Party. *Eur J Cancer* 1997 May;33(6):829-35.
<http://www.ncbi.nlm.nih.gov/pubmed/9291801>
218. Herr HW, Sheinfeld J, Puc HS, et al. Surgery for a post-chemotherapy residual mass in seminoma. *J Urol* 1997 Mar;157(3):860-2.
<http://www.ncbi.nlm.nih.gov/pubmed/9072586>
219. Mosharafa AA, Foster RS, Leibovich BC, et al. Is the post-chemotherapy resection of seminomatous elements associated with higher acute morbidity? *J Urol* 2003 Jun;169(6):2126-8.
<http://www.ncbi.nlm.nih.gov/pubmed/12771733>
220. Puc H, Heelan R, Mazumdar M, et al. Management of residual mass in advanced seminoma: results and recommendations from the Memorial Sloan-Kettering Cancer Center. *J Clin Oncol* 1996 Feb;14(2):454-60.
<http://www.ncbi.nlm.nih.gov/pubmed/8636757>
221. Miki T, Mizutani Y, Nakamura T, et al. Post-chemotherapy nerve-sparing retroperitoneal lymph node dissection for advanced germ cell tumor. *Int J Urol* 2009 Apr;16(4):379-82.
<http://www.ncbi.nlm.nih.gov/pubmed/19191930>

222. Carver BS, Serio AM, Bajorin D, et al. Improved clinical outcome in recent years for men with metastatic nonseminomatous germ cell tumors. *J Clin Oncol* 2007 Dec 10;25(35):5603-8.
<http://www.ncbi.nlm.nih.gov/pubmed/17998544>
223. Kuczyk M, Machtens S, Stief C, et al. Management of the post-chemotherapy residual mass in patients with advanced stage non-seminomatous germ cell tumors (NSGCT). *Int J Cancer* 1999 Dec;83(6):852-5.
<http://www.ncbi.nlm.nih.gov/pubmed/10597210>
224. Toner GC, Panicek DM, Heelan RT, et al. Adjunctive surgery after chemotherapy for nonseminomatous germ cell tumors: recommendations for patient selection. *J Clin Oncol* 1990 Oct;8(10):1683-94.
<http://www.ncbi.nlm.nih.gov/pubmed/2170590>
225. Donohue JP, Rowland RG, Kopecky K, et al. Correlation of computerized tomographic changes and histological findings in 80 patients having radical retroperitoneal lymph node dissection after chemotherapy for testis cancer. *J Urol* 1987 Jun;137(6):1176-9.
<http://www.ncbi.nlm.nih.gov/pubmed/3035236>
226. Kollmannsberger C, Daneshmand S, So A, et al. Management of disseminated nonseminomatous germ cell tumors with risk-based chemotherapy followed by response-guided postchemotherapy surgery. *J Clin Oncol* 2010 Feb;28(4):537-42.
<http://www.ncbi.nlm.nih.gov/pubmed/20026807>
227. Ehrlich Y, Brames MJ, Beck SD, et al. Long-term follow-up of Cisplatin combination chemotherapy in patients with disseminated nonseminomatous germ cell tumors: is a postchemotherapy retroperitoneal lymph node dissection needed after complete remission? *J Clin Oncol* 2010 Feb;28(4):531-6.
<http://www.ncbi.nlm.nih.gov/pubmed/20026808>
228. Rabbani F, Goldenberg SL, Gleave ME, et al. Retroperitoneal lymphadenectomy for postchemotherapy residual masses: is a modified dissection and resection of residual masses sufficient? *Br J Urol* 1998 Feb;81(2):295-300.
<http://www.ncbi.nlm.nih.gov/pubmed/9488075>
229. Tekgul S, Ozen HA, Celebi I, et al. Postchemotherapeutic surgery for metastatic testicular germ cell tumors: results of extended primary chemotherapy and limited surgery. *Urology* 1994 Mar;43(3):349-54.
<http://www.ncbi.nlm.nih.gov/pubmed/8134989>
230. Steyerberg EW, Keizer HJ, Fosså SD, et al. Prediction of residual retroperitoneal mass histology after chemotherapy for metastatic nonseminomatous germ cell tumour: multivariate analysis of individual patient data from six study groups. *J Clin Oncol* 1995 May;13(5):1177-87.
<http://www.ncbi.nlm.nih.gov/pubmed/7537801>
231. Hartmann JT, Candelaria M, Kuczyk MA, et al. Comparison of histological results from the resection of residual masses at different sites after chemotherapy for metastatic nonseminomatous germ cell tumours. *Eur J Cancer* 1997 May;33(6):843-7.
<http://www.ncbi.nlm.nih.gov/pubmed/9291803>
232. Vergouwe Y, Steyerberg EW, De Wit R, et al. External validity of a prediction rule for residual mass histology in testicular cancer: an evaluation for good prognosis patients. *Br J Cancer* 2003 Mar;88(6):843-7.
<http://www.ncbi.nlm.nih.gov/pubmed/12644820>
233. Weinknecht S, Hartmann M, Weissbach L. [In which marker-positive patients with germ cell tumors is residual tumor resection of value?] *Urologe A* 1998 Nov;37(6):621-4. [Article in German]
<http://www.ncbi.nlm.nih.gov/pubmed/9887490>
234. Hendry WF, Norman AR, Dearnaley DP, et al. Metastatic nonseminomatous germ cell tumors of the testis: results of elective and salvage surgery for patients with residual retroperitoneal masses. *Cancer* 2002 Mar;94(6):1668-76.
<http://www.ncbi.nlm.nih.gov/pubmed/11920527>
235. Sheinfeld J. The role of adjunctive postchemotherapy surgery for nonseminomatous germ-cell tumors: current concepts and controversies. *Semin Urol Oncol* 2002 Nov;20(4):262-71.
<http://www.ncbi.nlm.nih.gov/pubmed/12489059>
236. Foster RS, Donohue JP. Can retroperitoneal lymphadenectomy be omitted in some patients after chemotherapy? *Urol Clin North Am* 1998 Aug;25(3):479-84.
<http://www.ncbi.nlm.nih.gov/pubmed/9728217>

237. Steyerberg EW, Kaiser HJ, Habbema JD. Prediction models for the histology of residual masses after chemotherapy for metastatic testicular cancer. ReHiT Study Group. *Int J Cancer* 1999 Dec;83(6):856-9.
<http://www.ncbi.nlm.nih.gov/pubmed/10597211>
238. Carver BS, Shayegan B, Serio A, et al. Long-term clinical outcome after postchemotherapy retroperitoneal lymph node dissection in men with residual teratoma. *J Clin Oncol* 2007 Mar;25(9):1033-7.
<http://www.ncbi.nlm.nih.gov/pubmed/17261854>
239. Hartmann JT, Schmoll HJ, Kuczyk MA, et al. Postchemotherapy resections of residual masses from metastatic non-seminomatous germ cell tumors. *Ann Oncol* 1997 Jun;8(6):531-8.
<http://www.ncbi.nlm.nih.gov/pubmed/9261521>
240. Oldenburg J, Alfsen GC, Lien HH, et al. Postchemotherapy retroperitoneal surgery remains necessary in patients with nonseminomatous testicular cancer and minimal residual tumor masses. *J Clin Oncol* 2003 Sep;21(17):3310-7.
<http://www.ncbi.nlm.nih.gov/pubmed/12947067>
241. Rick O, Bokemeyer C, Weinknecht S, et al. Residual tumor resection after high-dose chemotherapy in patients with relapsed or refractory germ cell cancer. *J Clin Oncol* 2004 Sep;22(18):3713-9.
<http://www.ncbi.nlm.nih.gov/pubmed/15365067>
242. Aprikian AG, Herr HW, Bajorin DF, et al. Resection of postchemotherapy residual masses and limited retroperitoneal lymphadenectomy in patients with metastatic testicular nonseminomatous germ cell tumors. *Cancer* 1994 Aug;74(4):1329-34.
<http://www.ncbi.nlm.nih.gov/pubmed/8055456>
243. Herr HW. Does necrosis on frozen-section analysis of a mass after chemotherapy justify a limited retroperitoneal resection in patients with advanced testis cancer? *Br J Urol* 1997 Oct;80(4):653-7.
<http://www.ncbi.nlm.nih.gov/pubmed/9352708>
244. Hendry WF, A'Hern RP, Hetherington JW, et al. Para-aortic lymphadenectomy after chemotherapy for metastatic non-seminomatous germ cell tumours: prognostic value and therapeutic benefit. *Br J Urol* 1993 Feb;71(2):208-13.
<http://www.ncbi.nlm.nih.gov/pubmed/8384914>
245. Wood DP Jr, Herr HW, Heller G, et al. Distribution of retroperitoneal metastases after chemotherapy in patients with nonseminomatous germ cell tumors. *J Urol* 1992 Dec;148(6):1812-5.
<http://www.ncbi.nlm.nih.gov/pubmed/1331547>
246. Baniel J, Foster RS, Rowland RG, et al. Complications of post-chemotherapy retroperitoneal lymph node dissection. *J Urol* 1995 Mar;153(3 Pt 2):976-80.
<http://www.ncbi.nlm.nih.gov/pubmed/7853586>
247. Fizazi K, Oldenburg J, Dunant A, et al. Assessing prognosis and optimizing treatment in patients with postchemotherapy viable nonseminomatous germ-cell tumors (NSGCT): results of the sCR2 international study. *Ann Oncol* 2008 Feb;19(2):259-64.
<http://www.ncbi.nlm.nih.gov/pubmed/18042838>
248. Steiner H, Peschel R, Bartsch G. Retroperitoneal lymph node dissection after chemotherapy for germ cell tumours: is a full bilateral template always necessary? *BJU Int* 2008 Aug;102(3):310-4.
<http://www.ncbi.nlm.nih.gov/pubmed/18325053>
249. Heidenreich A, Pfister D, Witthuhn R, et al. Postchemotherapy retroperitoneal lymph node dissection in advanced testicular cancer: radical or modified template resection. *Eur Urol* 2009 Jan;55(1):217-24.
<http://www.ncbi.nlm.nih.gov/pubmed/18926622>
250. Beck SD, Foster RS, Bihrl R, et al. Is full bilateral retroperitoneal lymph node dissection always necessary for postchemotherapy residual tumor? *Cancer* 2007 Sep;110(6):1235-40.
<http://www.ncbi.nlm.nih.gov/pubmed/17665498>
251. Calestroupat JP, Sanchez-Salas R, Cathelineau X, et al. Postchemotherapy laparoscopic retroperitoneal lymph node dissection in nonseminomatous germ-cell tumor. *J Endourol* 2009 Apr;23(4):645-50.
<http://www.ncbi.nlm.nih.gov/pubmed/19335332>
252. Busch J, Magheli A, Erber B, et al. Laparoscopic and open postchemotherapy retroperitoneal lymph node dissection in patients with advanced testicular cancer--a single center analysis. *BMC Urol* 2012 May;12:15.
<http://www.ncbi.nlm.nih.gov/pubmed/22651395>

253. Arai Y, Kaiho Y, Yamada S, et al. Extraperitoneal laparoscopic retroperitoneal lymph node dissection after chemotherapy for nonseminomatous testicular germ-cell tumor: surgical and oncological outcomes. *Int Urol Nephrol* 2012 Oct;44(5):1389-95.
<http://www.ncbi.nlm.nih.gov/pubmed/22648291>
254. Steyerberg EW, Donohue JP, Gerl A, et al. Residual masses after chemotherapy for metastatic testicular cancer: the clinical implications of the association between retroperitoneal and pulmonary histology. Re-analysis of Histology in Testicular Cancer (ReHiT) Study Group. *J Urol* 1997 Aug;158(2):474-8.
<http://www.ncbi.nlm.nih.gov/pubmed/9010108>
255. Besse B, Grunenwald D, Fléchon A, et al. Nonseminomatous germ cell tumors: assessing the need for postchemotherapy contralateral pulmonary resection in patients with ipsilateral complete necrosis. *J Thorac Cardiovasc Surg* 2009 Feb;137(2):448-52.
<http://www.ncbi.nlm.nih.gov/pubmed/19185168>
256. Schirren J, Trainer S, Eberlein M, et al. The role of residual tumor resection in the management of nonseminomatous germ cell cancer of testicular origin. *Thorac Cardiovasc Surg* 2012 Sep;60(6):405-12.
<http://www.ncbi.nlm.nih.gov/pubmed/22383152>
257. Ehrlich Y, Kedar D, Zelikovski A, et al. Vena caval reconstruction during postchemotherapy retroperitoneal lymph node dissection for metastatic germ cell tumor. *Urology* 2009 Feb;73(2):442 e17-9.
<http://www.ncbi.nlm.nih.gov/pubmed/18436290>
258. Beck SD, Foster RS, Bihrlé R, et al. Aortic replacement during post-chemotherapy retroperitoneal lymph node dissection. *J Urol* 2001 May;165(5):1517-20.
<http://www.ncbi.nlm.nih.gov/pubmed/11342909>
259. Winter C, Pfister D, Busch J, et al. Residual tumor size and IGCCCG risk classification predict additional vascular procedures in patients with germ cell tumors and residual tumor resection: a multicenter analysis of the German Testicular Cancer Study Group. *Eur Urol* 2012 Feb;61(2):403-9.
<http://www.ncbi.nlm.nih.gov/pubmed/22078334>
260. Eggener SE, Carver BS, Loeb S, et al. Pathologic findings and clinical outcome of patients undergoing retroperitoneal lymph node dissection after multiple chemotherapy regimens for metastatic testicular germ cell tumors. *Cancer* 2007 Feb 1;109(3):528-35.
<http://www.ncbi.nlm.nih.gov/pubmed/17177200>
261. Oechsle K, Kollmannsberger C, Honecker F, et al. Long-term survival after treatment with gemcitabine and oxaliplatin with and without paclitaxel plus secondary surgery in patients with cisplatin-refractory and/or multiply relapsed germ cell tumors. *Eur Urol* 2011 Oct;60(4):850-5.
<http://www.ncbi.nlm.nih.gov/pubmed/21704446>
262. Nicolai N, Necchi A, Gianni L, et al. Long-term results of a combination of paclitaxel, cisplatin and gemcitabine for salvage therapy in male germ-cell tumours. *BJU Int* 2009 Aug;104(3):340-6.
<http://www.ncbi.nlm.nih.gov/pubmed/19239440>
263. Beck SD, Foster RS, Bihrlé R, et al. Outcome analysis for patients with elevated serum tumor markers at postchemotherapy retroperitoneal lymph node dissection. *J Clin Oncol* 2005 Sep 1;23(25):6149-56.
<http://www.ncbi.nlm.nih.gov/pubmed/16135481>
264. Fizazi K, Tjulandin S, Salvioni R, et al. Viable malignant cells after primary chemotherapy for disseminated nonseminomatous germ cell tumors: prognostic factors and role of postsurgery chemotherapy—results from an international study group. *J Clin Oncol* 2001 May;19(10):2647-57.
<http://www.ncbi.nlm.nih.gov/pubmed/11352956>
265. Stenning SP, Parkinson MC, Fisher C, et al. Postchemotherapy residual masses in germ cell tumor patients: content, clinical features and prognosis. Medical Research Council Testicular Tumour Working Party. *Cancer* 1998 Oct;83(7):1409-19.
<http://www.ncbi.nlm.nih.gov/pubmed/9762943>
266. Miller KD, Loehrer PJ, Gonin R, et al. Salvage chemotherapy with vinblastine, ifosfamide and cisplatin in recurrent seminoma. *J Clin Oncol* 1997 Apr;15(4):1427-31.
<http://www.ncbi.nlm.nih.gov/pubmed/9193335>
267. Fizazi K, Gravis G, Fléchon A, et al. Combining gemcitabine, cisplatin, and ifosfamide (GIP) is active in patients with relapsed metastatic germ-cell tumors (GCT): a prospective multicenter GETUG phase II trial. *Ann Oncol* 2014 May;25(5):987-91.
<http://www.ncbi.nlm.nih.gov/pubmed/24595454>

268. Pico JL, Rosti G, Kramar A, et al. Genito-Urinary Group of the French Federation of Cancer Centers (GETUG-FNCLCC), France; European Group for Blood and Marrow Transplantation (EBMT). A randomised trial of high-dose chemotherapy in the salvage treatment of patients failing first-line platinum chemotherapy for advanced germ cell tumours. *Ann Oncol* 2005 Jul;16(7):1152-9. <http://www.ncbi.nlm.nih.gov/pubmed/15928070>
269. Lorch A, Kollmannsberger C, Hartmann JT, et al. German Testicular Cancer Study Group. Single versus sequential high-dose chemotherapy in patients with relapsed or refractory germ cell tumors: a prospective randomized multicenter trial of the German Testicular Cancer Study Group. *J Clin Oncol* 2007 Jul;25(19):2778-84. <http://www.ncbi.nlm.nih.gov/pubmed/17602082>
270. International Prognostic Factors Study Group, Lorch A, Beyer J, Bascoul-Mollevi C, et al. Prognostic factors in patients with metastatic germ cell tumors who experienced treatment failure with cisplatinbased first-line chemotherapy. *J Clin Oncol* 2010 Nov;28(33):4906-11. <http://www.ncbi.nlm.nih.gov/pubmed/20956623>
271. Oechsle K, Lorch A, Honecker F, et al. Patterns of relapse after chemotherapy in patients with highrisk non-seminomatous germ cell tumor. *Oncology* 2010;78(1):47-53. <http://www.ncbi.nlm.nih.gov/pubmed/20215785>
272. Lorch A, Kleinhans A, Kramar A, et al. Sequential versus single high-dose chemotherapy in patients with relapsed or refractory germ cell tumors: long-term results of a prospective randomized trial. *J Clin Oncol* 2012 Mar 10;30(8):800-5. <http://www.ncbi.nlm.nih.gov/pubmed/22291076>
273. Mead GM, Cullen MH, Huddart R, et al. MRC Testicular Tumour Working Party. A phase II trial of TIP (paclitaxel, ifosfamide and cisplatin) given as second-line (post-BEP) salvage chemotherapy for patients with metastatic germ cell cancer: a medical research council trial. *Br J Cancer* 2005 Jul;93(2):178-84. <http://www.ncbi.nlm.nih.gov/pubmed/15999102>
274. Segal R, Lukka H, Klotz LH, et al. Cancer Care Ontario Practice Guidelines Initiative Genitourinary Cancer Disease Site Group. Surveillance programs for early stage nonseminomatous testicular cancer: a practice guideline. *Can J Urol* 2001 Feb;8(1):1184-92. <http://www.ncbi.nlm.nih.gov/pubmed/11268306>
275. Necchi A, Nicolai N, Mariani L, et al. Combination of paclitaxel, cisplatin, and gemcitabine (TPG) for multiple relapses or platinum-resistant germ cell tumors: long-term outcomes. *Clin Genitourin cancer* 2014 Feb;12(1):63-9 e1. <http://www.ncbi.nlm.nih.gov/pubmed/24161525>
276. Oldenburg J, Martin JM, Fossa SD. Late relapses of germ cell malignancies: incidence, management, and prognosis. *J Clin Oncol* 2006 Dec;24(35):5503-11. <http://www.ncbi.nlm.nih.gov/pubmed/17158535>
277. Beyer J, Albers P, Altena R, et al. Maintaining success, reducing treatment burden, focusing on survivorship: highlights from the third European consensus conference on diagnosis and treatment of germ-cell cancer. *Ann Oncol* 2013 Apr;24(4):878-88. <http://www.ncbi.nlm.nih.gov/pubmed/23152360>
278. Baniel J, Foster RS, Einhorn LH, et al. Late relapse of clinical stage I testicular cancer. *J Urol* 1995 Oct;154(4):1370-2. <http://www.ncbi.nlm.nih.gov/pubmed/7658541>
279. George DW, Foster RS, Hromas RA, et al. Update on late relapse of germ cell tumor: a clinical and molecular analysis. *J Clin Oncol* 2003 Jan;21(1):113-22. <http://www.ncbi.nlm.nih.gov/pubmed/12506179>
280. Oldenburg J, Alfsen GC, Waehre H, et al. Late recurrences of germ cell malignancies: a population-based experience over three decades. *Br J Cancer* 2006 Mar 27;94(6):820-7. <http://www.ncbi.nlm.nih.gov/pubmed/16508636>
281. Lee AH, Mead GM, Theaker JM. The value of central histopathological review of testicular tumours before treatment. *BJU Int* 1999 Jul;84(1):75-8. <http://www.ncbi.nlm.nih.gov/pubmed/10444128>
282. Lipphardt ME, Albers P. Late relapse of testicular cancer. *World J Urol* 2004 Apr;22(1):47-54. <http://www.ncbi.nlm.nih.gov/pubmed/15064970>
283. Fosså SD, Bokemeyer C, Gerl A, et al. Treatment outcome of patients with brain metastases from malignant germ cell tumors. *Cancer* 1999 Feb;85(4):988-97. <http://www.ncbi.nlm.nih.gov/pubmed/10091779>

284. Bokemeyer C, Nowak P, Haupt A, et al. Treatment of brain metastases in patients with testicular cancer. *J Clin Oncol* 1997 Apr;15(4):1449-54.
<http://www.ncbi.nlm.nih.gov/pubmed/9193339>
285. Hartmann JT, Bamberg M, Albers P, et al. Multidisciplinary treatment and prognosis of patients with central nervous metastases (CNS) from testicular germ cell tumour (GCT) origin. *Proc Ann Soc Clin Oncol* 2003;22:400, abstr 1607.
http://www.asco.org/ASCOv2/Meetings/Abstracts?&vmview=abst_detail_view&confID=23&abstractID=103455
286. Rathmell AJ, Brand IR, Carey BM, et al. Early detection of relapse after treatment for metastatic germ cell tumour of the testis: an exercise in medical audit. *Clin Oncol (R Coll Radiol)* 1993;5(1):34-8.
<http://www.ncbi.nlm.nih.gov/pubmed/7678749>
287. Gietema JA, Meinardi MT, Sleijfer DT, et al. Routine chest X-rays have no additional value in the detection of relapse during routine follow-up of patients treated with chemotherapy for disseminated non-seminomatous testicular cancer. *Ann Oncol* 2002 Oct;13(10):1616-20.
<http://www.ncbi.nlm.nih.gov/pubmed/12377651>
288. Brenner DJ, Hall EJ. Computed tomography: an increasing source of radiation exposure. *N Engl J Med* 2007 Nov;357(22):2277-84.
<http://www.ncbi.nlm.nih.gov/pubmed/18046031>
289. Schmoll HJ, Jordan K, Huddart R, et al. ESMO Guidelines Working Group. Testicular non-seminoma: ESMO Clinical Practice Guidelines for diagnosis, treatment and follow-up. *Ann Oncol* 2010 May;21 Suppl :v147-54.
http://annonc.oxfordjournals.org/content/21/suppl_5/v147.long
290. Schmoll HJ, Jordan K, Huddart R, et al. ESMO Guidelines Working Group. Testicular non-seminoma: ESMO clinical recommendations for diagnosis, treatment and follow-up. *Ann Oncol* 2009 May;20 Suppl 4:89-96.
http://annonc.oxfordjournals.org/content/20/suppl_4/iv89.long
291. Cathomas R, Helbling D, Stenner F, et al. Interdisciplinary evidence-based recommendations for the follow-up of testicular cancer patients: a joint effort. *Swiss Med Wkly* 2010;140 (25-26):356-69.
<http://www.smw.ch/for-readers/archive/backlinks?url=/docs/pdfcontent/smw-12993.pdf>
292. Ondrus D, Goncalves F, Kausitz J, et al. The value of prognostic factors in the management of stage I nonseminomatous germ cell testicular tumors (NSGCTT). *Neoplasma* 1996;43(3):195-7.
<http://www.ncbi.nlm.nih.gov/pubmed/8841507>
293. Tjan-Heijnen VC, Oosterhof GO, de Wit R, et al. Treatment of germ cell tumours: state of the art. *Eur J Surg Oncol* 1997 Apr;23(2):110-7.
<http://www.ncbi.nlm.nih.gov/pubmed/9158183>
294. Lowe BA. Surveillance versus nerve-sparing retroperitoneal lymphadenectomy in stage I germ cell tumors. *Urol Clin North Am* 1993 Feb;20(1):75-83.
<http://www.ncbi.nlm.nih.gov/pubmed/8381999>
295. Kollmannsberger C, Tandstad T, Bedard PL, et al. Patterns of relapse in patients with clinical stage I testicular cancer managed with active surveillance. *J Clin Oncol* 2015 Jan;33(1):51-7.
<http://www.ncbi.nlm.nih.gov/pubmed/25135991>
296. Gels ME, Hoekstra HJ, Sleijfer DT, et al. Detection of recurrence in patients with clinical stage I nonseminomatous testicular germ cell tumors and consequences for further follow-up: a single-center 10-year experience. *J Clin Oncol* 1995 May;13(5):1188-94.
<http://www.ncbi.nlm.nih.gov/pubmed/7537802>
297. McLeod DG, Weiss RB, Stablein DM, et al. Staging relationships and outcome in early stage testicular cancer: a report from the Testicular Cancer Intergroup Study. *J Urol* 1991 Jun;145(6):1178-83.
<http://www.ncbi.nlm.nih.gov/pubmed/1851890>
298. Donohue JP, Thornhill JA, Foster RS, et al. Primary retroperitoneal lymph node dissection in clinical stage A non-seminomatous germ cell testis cancer: review of the Indiana University Experience 1965-1989. *Br J Urol* 1993 Mar;71(3):326-35.
<http://www.ncbi.nlm.nih.gov/pubmed/8386580>
299. Schmoll HJ, Weissbach L. [Diagnostik und Therapie von Hodentumoren.] Interdisziplinäre Konsensus-Konferenz, Halle (Saale), 1996. EBM IIa, IIb, III. [Diagnosis and therapy for germ cell tumours] [Article in German]
300. McCaffrey JA, Bajorin DF, Motzer RJ. Risk assessment for metastatic testis cancer. *Urol Clin North Am* 1998 Aug;25(3):389-95.
<http://www.ncbi.nlm.nih.gov/pubmed/9728209>

301. Sultanem K, Souhami L, Benk V, et al. Para-aortic irradiation only appears to be adequate treatment for patients with stage I seminoma of the testis. *Int J Radiat Oncol Biol Phys* 1998 Jan;40(2):455-9. <http://www.ncbi.nlm.nih.gov/pubmed/9457835>
302. Warde P, Gospodarowicz MK, Panzarella T, et al. Stage I testicular seminoma: results of adjuvant irradiation and surveillance. *J Clin Oncol* 1995 Sep;13(9):2255-62. <http://www.ncbi.nlm.nih.gov/pubmed/7666083>
303. Tana S, Cerrotta A, Gardani G, et al. Postsurgical policy in stage I testicular seminoma: cost and benefit of prophylactic irradiation in a long-term experience. *Tumouri* 1997 Nov-Dec;83(6):918-21. <http://www.ncbi.nlm.nih.gov/pubmed/9526584>
304. Fosså SD, Aass N, Kaalhus O. Radiotherapy for testicular seminoma stage I: treatment results and long-term post-irradiation morbidity in 365 patients. *Int J Radiat Oncol Biol Phys* 1989 Feb;16(2):383-8. <http://www.ncbi.nlm.nih.gov/pubmed/2921142>
305. Stein ME, Leviov M, Drumea K, et al. Radiation-induced tumors in irradiated stage I testicular seminoma: results of a 25-year follow-up (1968-1993). *J Surg Oncol* 1998 Jan;67(1):38-40. <http://www.ncbi.nlm.nih.gov/pubmed/9457255>
306. Akimoto T, Takahashi I, Takahashi M, et al. Long-term outcome of postorchidectomy radiation therapy for stage I and II testicular seminoma. *Anticancer Res* 1997 Sep-Oct;17(5B):3781-5. <http://www.ncbi.nlm.nih.gov/pubmed/9427780>
307. Huddart RA, Joffe JK. Preferred treatment for stage I seminoma: a survey of Canadian radiation oncologists. *Clin Oncol (R Coll Radiol)* 2006 Nov;18(9):693-5. [No abstract available] <http://www.ncbi.nlm.nih.gov/pubmed/17100155>
308. Krege S, Kalund G, Otto T, et al. Phase II study: adjuvant single-agent carboplatin therapy for clinical stage I seminoma. *Eur Urol* 1997;31(4):405-7. <http://www.ncbi.nlm.nih.gov/pubmed/9187898>
309. Dieckmann KP, Krain J, Küster J, et al. Adjuvant carboplatin treatment for seminoma clinical stage I. *J Cancer Res Clin Oncol* 1996;122(1):63-6. <http://www.ncbi.nlm.nih.gov/pubmed/8543595>
310. Bukowski RM. Management of advanced and extragonadal germ-cell tumors. *Urol Clin North Am* 1993 Feb;20(1):153-60. <http://www.ncbi.nlm.nih.gov/pubmed/8381995>
311. Fair W, Dalbagni G, Machele Donat S, et al. Evaluation and follow-up of patients with urologic cancer. AUA Office of Education Publications 9958 PG, 1999.
312. Fosså SD, Chen J, Schonfeld SJ, et al. Risk of contralateral testicular cancer: a population-based study of 29,515 U.S. men. *J Natl Cancer Inst* 2005 Jul;97(14):1056-66. <http://www.ncbi.nlm.nih.gov/pubmed/16030303>
313. Wierecky J, Kollmannsberger C, Boehlke I, et al. Secondary leukemia after first-line high-dose for patients with advanced germ cell cancer. *J Cancer Res Clin Oncol* 2005 Apr;131(4):255-60. <http://www.ncbi.nlm.nih.gov/pubmed/15627215>
314. Nuver J, Smit AJ, Sleijfer DT, et al. Left ventricular and cardiac autonomic function in survivors of testicular cancer. *Eur J Clin Invest* 2005 Feb;35(2):99-103. <http://www.ncbi.nlm.nih.gov/pubmed/15667580>
315. van den Belt-Dusebout AW, Nuver J, de Wit R, et al. Long-term risk of cardiovascular disease in 5-year survivors of testicular cancer. *J Clin Oncol* 2006 Jan;24(3):467-75. <http://www.ncbi.nlm.nih.gov/pubmed/16421423>
316. Haugnes HS, Aass N, Fosså SD, et al. Components of the metabolic syndrome in long-term survivors of testicular cancer. *Ann Oncol* 2007 Feb;18(2):241-8. <http://www.ncbi.nlm.nih.gov/pubmed/17060482>
317. Pizzocaro G. Non-seminomatous germ-cell tumours (NSGCT) of the testis: diagnosis and management, stage by stage. *Eur Urol Update Series* 1997;6:139-45.
318. Little JS Jr, Foster RS, Ulbright TM, et al. Unusual neoplasms detected in testis cancer patients undergoing post-chemotherapy retroperitoneal lymphadenectomy. *J Urol* 1994 Oct;152(4):1144-9. <http://www.ncbi.nlm.nih.gov/pubmed/8072083>
319. Travis LB, Beard C, Allan JM, et al. Testicular cancer survivorship: research strategies and recommendations. *J Natl Cancer Inst* 2010 Aug 4;102(15):1114-30. <http://www.ncbi.nlm.nih.gov/pubmed/20585105>
320. Oldenburg J, Aparicio J, Beyer J, et al. Personalizing, not patronizing: The case for patient autonomy by unbiased presentation of management options in stage I testicular cancer. *Ann Oncol* 2014 Nov; in press <http://annonc.oxfordjournals.org/content/early/2014/11/06/annonc.mdu514.abstract>

321. Vidal A, Thalmann GN, Karamitopoulou E, et al. Long term outcome of patients with clinical stage I high-risk nonseminomatous germ cell tumors 15 years after one adjuvant cycle of Bleomycin, Etoposide and Cisplatin chemotherapy. *Ann Oncol* 2015 Feb;26(2):374-7.
<http://www.ncbi.nlm.nih.gov/pubmed/25392157>
322. Haugnes HS, Bosl GJ, Boer H, et al. Long-term and late effects of germ cell testicular cancer treatment and implications for follow-up. *J Clin Oncol* 2012 Oct 20;30(30):3752-63.
<http://www.ncbi.nlm.nih.gov/pubmed/23008318>
323. Fosså S, Oldenburg J, Dahl AA. Short- and long-term morbidity after treatment for testicular cancer. *BJU Int* 2009 Nov;104(9 Pt B):1418-22.
<http://www.ncbi.nlm.nih.gov/pubmed/19840023>
324. Hemminki K, Liu H, Sundquist J. Second cancers after testicular cancer diagnosed after 1980 in Sweden. *Ann Oncol* 2010 Jul;21(7):1546-51.
<http://www.ncbi.nlm.nih.gov/pubmed/20019089>
325. Richiardi L, Scélo G, Boffetta P, et al. Second malignancies among survivors of germ-cell testicular cancer: a pooled analysis between 13 cancer registries. *Int J Cancer* 2007 Feb 1;120(3):623-31.
<http://www.ncbi.nlm.nih.gov/pubmed/17096341>
326. Travis LB, Fosså SD, Schonfeld SJ, et al. Second cancers among 40,576 testicular cancer patients: focus on long-term survivors. *J Natl Cancer Inst* 2005 Sep 21;97(18):1354-65.
<http://www.ncbi.nlm.nih.gov/pubmed/16174857>
327. Wanderås EH, Fosså SD, Tretli S. Risk of subsequent non-germ cell cancer after treatment of germ cell cancer in 2006 Norwegian male patients. *Eur J Cancer* 1997 Feb;33(2):253-62.
<http://www.ncbi.nlm.nih.gov/pubmed/9135497>
328. Bokemeyer C, Schmoll HJ. Treatment of testicular cancer and the development of secondary malignancies. *J Clin Oncol* 1995 Jan;13(1):283-92.
<http://www.ncbi.nlm.nih.gov/pubmed/7799032>
329. Fung C, Fossa SD, Milano MT, et al. Solid tumors after chemotherapy or surgery for testicular nonseminoma: a population-based study. *J Clin Oncol* 2013 Oct 20;31(30):3807-14.
<http://www.ncbi.nlm.nih.gov/pubmed/24043737>
330. Howard R, Gilbert E, Lynch CF, et al. Risk of leukemia among survivors of testicular cancer: a population-based study of 42,722 patients. *Ann Epidemiol* 2008 May;18(5):416-21.
<http://www.ncbi.nlm.nih.gov/pubmed/18433667>
331. Kollmannsberger C, Beyer J, Droz JP, et al. Secondary leukemia following high cumulative doses of etoposide in patients treated for advanced germ cell tumors. *J Clin Oncol* 1998 Oct;16(10):3386-91.
<http://www.ncbi.nlm.nih.gov/pubmed/9779717>
332. Nichols CR, Breeden ES, Loehrer PJ, et al. Secondary leukemia associated with a conventional dose of etoposide: review of serial germ cell tumor protocols. *J Natl Cancer Inst* 1993 Jan 6;85(1):36-40.
<http://www.ncbi.nlm.nih.gov/pubmed/7677934>
333. Fosså SD, Gilbert E, Dores GM, et al. Noncancer causes of death in survivors of testicular cancer. *J Natl Cancer Inst* 2007 Apr 4;99(7):533-44.
<http://www.ncbi.nlm.nih.gov/pubmed/17405998>
334. O'Sullivan JM, Huddart RA, Norman AR, et al. Predicting the risk of bleomycin lung toxicity in patients with germ-cell tumours. *Ann Oncol* 2003 Jan;14(1):91-6.
<http://www.ncbi.nlm.nih.gov/pubmed/12488299>
335. Haugnes HS, Aass N, Fosså SD, et al. Pulmonary function in long-term survivors of testicular cancer. *J Clin Oncol* 2009 Jun 10;27(17):2779-86.
<http://www.ncbi.nlm.nih.gov/pubmed/19414680>
336. Fosså SD, Aass N, Harvei S, et al. Increased mortality rates in young and middle-aged patients with malignant germ cell tumours. *Br J Cancer* 2004 Feb 9;90(3):607-12.
<http://www.ncbi.nlm.nih.gov/pubmed/14760372>
337. Alberti KG, Zimmet P, Shaw J, et al. The metabolic syndrome--a new worldwide definition. *Lancet* 2005 Sep 24-30;366(9491):1059-62.
<http://www.ncbi.nlm.nih.gov/pubmed/16182882>
338. Sprauten M, Darrah TH, Peterson DR, et al. Impact of long-term serum platinum concentrations on neuro- and ototoxicity in Cisplatin-treated survivors of testicular cancer. *J Clin Oncol* 2012 Jan 20;30(3):300-7.
<http://www.ncbi.nlm.nih.gov/pubmed/22184390>
339. Teutsch C, Lipton A, Harvey HA. Raynaud's phenomenon as a side effect of chemotherapy with vinblastine and bleomycin for testicular carcinoma. *Cancer Treat Rep* 1977 Aug;61(5):925-6.
<http://www.ncbi.nlm.nih.gov/pubmed/70274>

340. Adoue D, Arlet P. Bleomycin and Raynaud's phenomenon. *Ann Intern Med* 1984 May;100(5):770.
<http://www.ncbi.nlm.nih.gov/pubmed/6201095>
341. Vogelzang NJ, Bosl GJ, Johnson K, et al. Raynaud's phenomenon: a common toxicity after combination chemotherapy for testicular cancer. *Ann Intern Med* 1981 Sep;95(3):288-92.
<http://www.ncbi.nlm.nih.gov/pubmed/6168223>
342. Brydøy M, Oldenburg J, Klepp O, et al. Observational study of prevalence of long-term Raynaud-like phenomena and neurological side effects in testicular cancer survivors. *J Natl Cancer Inst* 2009 Dec 16;101(24):1682-95.
<http://www.ncbi.nlm.nih.gov/pubmed/19940282>
343. Bauer CA, Brozoski TJ. Cochlear structure and function after round window application of ototoxins. *Hear Res* 2005 Mar;201(1-2):121-31.
<http://www.ncbi.nlm.nih.gov/pubmed/15721567>
344. Bokemeyer C, Berger CC, Hartmann JT, et al. Analysis of risk factors for cisplatin-induced ototoxicity in patients with testicular cancer. *Br J Cancer* 1998 Apr;77(8):1355-62.
<http://www.ncbi.nlm.nih.gov/pubmed/9579846>
345. Osanto S, Bukman A, Van Hoek F, et al. Long-term effects of chemotherapy in patients with testicular cancer. *J Clin Oncol* 1992 Apr;10(4):574-9.
<http://www.ncbi.nlm.nih.gov/pubmed/1372350>
346. Oldenburg J, Fossa SD, Ikdahl T. Genetic variants associated with cisplatin-induced ototoxicity. *Pharmacogenomics* 2008 Oct;9(10):1521-30.
<http://www.ncbi.nlm.nih.gov/pubmed/18855538>
347. Oldenburg J, Kraggerud SM, Cvancarova M, et al. Cisplatin-induced long-term hearing impairment is associated with specific glutathione s-transferase genotypes in testicular cancer survivors. *J Clin Oncol* 2007 Feb 20;25(6):708-14.
<http://www.ncbi.nlm.nih.gov/pubmed/17228018>
348. Perry DJ, Weiss RB, Taylor HG. Enhanced bleomycin toxicity during acute renal failure. *Cancer Treat Rep* 1982 Mar;66(3):592-3.
<http://www.ncbi.nlm.nih.gov/pubmed/6174233>
349. Bennett WM, Pastore L, Houghton DC. Fatal pulmonary bleomycin toxicity in cisplatin-induced acute renal failure. *Cancer Treat Rep* 1980 Aug-Sep;64(8-9):921-4.
<http://www.ncbi.nlm.nih.gov/pubmed/6160913>
350. Sprauten M, Brydøy M, Haugnes HS, et al. Longitudinal serum testosterone, luteinizing hormone, and follicle-stimulating hormone levels in a population-based sample of long-term testicular cancer survivors. *J Clin Oncol* 2014 Feb;32(6):571-8.
<http://www.ncbi.nlm.nih.gov/pubmed/24419125>
351. Orre IJ, Fosså SD, Murison R, et al. Chronic cancer-related fatigue in long-term survivors of testicular cancer. *J Psychosom Res* 2008 Apr;64(4):363-71.
<http://www.ncbi.nlm.nih.gov/pubmed/18374735>
352. Fosså SD, Dahl AA, Loge JH. Fatigue, anxiety, and depression in long-term survivors of testicular cancer. *J Clin Oncol* 2003 Apr;21(7):1249-54.
<http://www.ncbi.nlm.nih.gov/pubmed/12663711>
353. Sprauten M, Haugnes HS, Brydøy M, et al. Fatigue in relation to treatment and gonadal function in a population-based sample of 796 testicular cancer survivors 12 and 19 years after treatment. *J Clin Oncol* 32:5s, 2014 (suppl; abstr 4564).
<http://meetinglibrary.asco.org/content/134564-144>
354. Fosså SD, de Wit R, Roberts JT, et al. Quality of life in good prognosis patients with metastatic germ cell cancer: a prospective study of the European Organization for Research and Treatment of Cancer Genitourinary Group/Medical Research Council Testicular Cancer Study Group (30941/TE20). *J Clin Oncol* 2003 Mar;21(6):1107-18.
<http://www.ncbi.nlm.nih.gov/pubmed/12637478>
355. Albers P FF, Flechtner H, Hartmann M, et al. Chemotherapy compared to surgery: Quality-of-life analysis of the German prospective multicenter trial in clinical stage I NSGCT (AUO AH 01/94). *J Clin Oncol* 2014;32(5s):(suppl; abstr 4563).
<http://meetinglibrary.asco.org/content/133252-144>
356. Kim I, Young RH, Scully RE. Leydig cell tumours of the testis. A clinicopathological analysis of 40 cases and review of the literature. *Am J Surg Pathol* 1985 Mar;9(3):177-92.
<http://www.ncbi.nlm.nih.gov/pubmed/3993830>
357. Ulbright TM, Amin MB, Young RH. Tumours of the testis, adnexia, spermatic cord and scrotum. *AFIP*1999.

358. Rock A, Marcelli F, Robin G, et al. [Clinical and paraclinical features of Klinefelter syndrome consulting for male infertility]. *Prog Urol* 2014 Oct;24(12):757-63. [Article in French].
<http://www.ncbi.nlm.nih.gov/pubmed/25193791>
359. Chevillet JC, Sebo TJ, Lager DJ, et al. Leydig cell tumour of the testis: a clinicopathologic, DNA content, and MIB-1 comparison of nonmetastasizing and metastasizing tumors. *Am J Surg Pathol* 1998 Nov;22(11):1361-7.
<http://www.ncbi.nlm.nih.gov/pubmed/9808128>
360. McCluggage WG, Shanks JH, Arthur K, et al. Cellular proliferation and nuclear ploidy assessments augment established prognostic factors in predicting malignancy in testicular Leydig cell tumours. *Histopathology* 1998 Oct;33(4):361-8.
<http://www.ncbi.nlm.nih.gov/pubmed/9822927>
361. Reznik Y, Rieu M, Kuhn JM, et al. Luteinizing hormone regulation by sex steroids in men with germinal and Leydig cell tumours. *Clin Endocrinol (Oxf)* 1993 May;38(5):487-93.
<http://www.ncbi.nlm.nih.gov/pubmed/8392454>
362. Suardi N, Strada E, Colombo R, et al. Leydig cell tumour of the testis: presentation, therapy, long-term follow-up and the role of organ-sparing surgery in a single-institution experience. *BJU int* 2009 Jan;103(2):197-200.
<http://www.ncbi.nlm.nih.gov/pubmed/18990169>
363. Bozzini G, Picozzi S, Gadda F, et al. Long-term follow-up using testicle-sparing surgery for Leydig cell tumor. *Clin Genitour Cancer* 2013 Sep;11(3):321-4.
<http://www.ncbi.nlm.nih.gov/pubmed/23317518>
364. Maizlin ZV, Belenky A, Kunichezky M, et al. Leydig cell tumors of the testis: gray scale and color Doppler sonographic appearance. *J Ultrasound Med* 2004 Jul;23(7):959-64.
<http://www.ncbi.nlm.nih.gov/pubmed/15292565>
365. Matveev BP, Gurarii LL. [Leydig-cell tumors of the testis] *Urol Nefrol (Mosk)* 1997 Jul-Aug;(4):34-6. [Article in Russian].
<http://www.ncbi.nlm.nih.gov/pubmed/9381620>
366. Di Tonno F, Tavolini IM, Belmonte P, et al. Lessons from 52 patients with leydig cell tumor of the testis: the GUONE (North-Eastern Uro-Oncological Group, Italy) experience. *Urol Int* 2009;82(2):152-7.
<http://www.ncbi.nlm.nih.gov/pubmed/19322000>
367. Loeser A, Verghe DC, Katzenberger T, et al. Testis-sparing surgery versus radical orchiectomy in patients with Leydig cell tumors. *Urology* 2009 Aug;74(2):370-2.
<http://www.ncbi.nlm.nih.gov/pubmed/19646624>
368. Leonhartsberger N, Ramoner R, Aigner F, et al. Increased incidence of Leydig cell tumours of the testis in the era of improved imaging techniques. *BJU Int* 2011 Nov;108(10):1603-7.
<http://www.ncbi.nlm.nih.gov/pubmed/21631694>
369. Young RH, Koelliker DD, Scully RE. Sertoli cell tumors of the testis, not otherwise specified: a clinicopathologic analysis of 60 cases. *Am J Surg Pathol* 1998 Jun;22(6):709-21.
<http://www.ncbi.nlm.nih.gov/pubmed/9630178>
370. Giglio M, Medica M, De Rose AF, et al. Testicular Sertoli cell tumours and relative sub-types. Analysis of clinical and prognostic features. *Urol Int* 2003;70(3):205-10.
<http://www.ncbi.nlm.nih.gov/pubmed/12660458>
371. Kratzer SS, Ulbright TM, Talerma A, et al. Large cell calcifying Sertoli cell tumour of the testis: contrasting features of six malignant and six benign tumors and a review of the literature. *Am J Surg Pathol* 1997 Nov;21(11):1271-80.
<http://www.ncbi.nlm.nih.gov/pubmed/9351565>
372. Henley JD, Young RH, Ulbright TM. Malignant Sertoli cell tumours of the testis: a study of 13 examples of a neoplasm frequently misinterpreted as seminoma. *Am J Surg Pathol* 2002 May;26:541-50.
<http://www.ncbi.nlm.nih.gov/pubmed/11979085>
373. Proppe KH, Scully RE. Large-cell calcifying Sertoli cell tumour of the testis. *Am J Clin Pathol* 1980 Nov;74(5):607-19.
<http://www.ncbi.nlm.nih.gov/pubmed/7446466>
374. Plata C, Algaba F, Andújar M, et al. Large cell calcifying Sertoli cell tumour of the testis. *Histopathology* 1995 Mar;26(3):255-9.
<http://www.ncbi.nlm.nih.gov/pubmed/7541015>
375. Zukerberg LR, Young RH, Scully RE. Sclerosing Sertoli cell tumour of the testis. A report of 10 cases. *Am J Surg Pathol* 1991 Sep;15(9):829-34.
<http://www.ncbi.nlm.nih.gov/pubmed/1719830>

376. Kao CS, Kum JB, Idrees MT, et al. Sclerosing Sertoli cell tumor of the testis: a clinicopathologic study of 20 cases. *Am J Surg Pathol* 2014 Apr;38(4):510-7.
<http://www.ncbi.nlm.nih.gov/pubmed/24552667>
377. Gierke CL, King BF, Bostwick DG, et al. Large-cell calcifying Sertoli cell tumour of the testis: appearance at sonography. *AJR Am J Roentgenol* 1994 Aug;163(2):373-5. [No abstract available]
<http://www.ncbi.nlm.nih.gov/pubmed/8037034>
378. Washecka R, Dresner MI, Honda SA. Testicular tumors in Carney's complex. *J Urol* 2002 Mar;167(3):1299-302.
<http://www.ncbi.nlm.nih.gov/pubmed/11832717>
379. Young S, Gooneratne S, Straus FH 2nd, et al. Feminizing Sertoli cell tumors in boys with Peutz-Jeghers syndrome. *Am J Surg Pathol* 1995 Jan;19(1):50-8.
<http://www.ncbi.nlm.nih.gov/pubmed/7802138>
380. Giannarini G, Dieckmann KP, Albers P, et al. Organ-sparing surgery for adult testicular tumours: a systematic review of the literature. *Eur Urol* 2010 May;57(5):780-90.
<http://www.ncbi.nlm.nih.gov/pubmed/20116165>
381. Mosharafa AA, Foster RS, Bihle R, et al. Does retroperitoneal lymph node dissection have a curative role for patients with sex cord-stromal testicular tumors? *Cancer* 2003 Aug;98(4):753-7.
<http://www.ncbi.nlm.nih.gov/pubmed/12910519>
382. Silberstein JL, Bazzi WM, Vertosick E, et al. Clinical outcomes of local and metastatic testicular sex cord-stromal tumors. *J Urol* 2014 Aug;192(2):415-9.
<http://www.ncbi.nlm.nih.gov/pubmed/24518791>
383. Featherstone JM, Fernando HS, Theaker JM, et al. Sex cord stromal testicular tumors: a clinical series--uniformly stage I disease. *J Urol* 2009 May;181(5):2090-6; discussion 6.
<http://www.ncbi.nlm.nih.gov/pubmed/19286222>
384. Shukla AR, Huff DS, Canning DA, et al. Juvenile granulosa cell tumor of the testis:: contemporary clinical management and pathological diagnosis. *J Urol* 2004 May;171(5):1900-2.
<http://www.ncbi.nlm.nih.gov/pubmed/15076304>
385. Zugor V, Labanaris AP, Witt J, et al. Congenital juvenile granulosa cell tumor of the testis in newborns. *Anticancer Res* 2010 May;30(5):1731-4.
<http://www.ncbi.nlm.nih.gov/pubmed/20592370>
386. Cornejo KM, Young RH. Adult granulosa cell tumors of the testis: a report of 32 cases. *Am J Surg Pathol* 2014 Sep;38(9):1242-50.
<http://www.ncbi.nlm.nih.gov/pubmed/24705318>
387. Miliaras D, Anagnostou E, Moysides I. Adult type granulosa cell tumor: a very rare case of sex-cord tumor of the testis with review of the literature. *Case reports in pathology* 2013;2013:932086.
<http://www.ncbi.nlm.nih.gov/pubmed/23762714>
388. Zhang M, Kao CS, Ulbright TM, et al. Testicular fibrothecoma: a morphologic and immunohistochemical study of 16 cases. *Am J Surg Pathol* 2013 Aug;37(8):1208-14.
<http://www.ncbi.nlm.nih.gov/pubmed/23715159>
389. Perito PE, Ciancio G, Civantos F, et al. Sertoli-Leydig cell testicular tumour: case report and review of sex cord/gonadal stromal tumour histogenesis. *J Urol* 1992 Sep;148(3):883-5.
<http://www.ncbi.nlm.nih.gov/pubmed/1512847>
390. Pleskacova J, Hersmus R, Oosterhuis JW, et al. Tumor risk in disorders of sex development. *Sex Dev* 2010 Sep;4(4-5):259-69.
<http://www.ncbi.nlm.nih.gov/pubmed/20558977>
391. Ulbright TM, Young RH. Gonadoblastoma and selected other aspects of gonadal pathology in young patients with disorders of sex development. *Semin Diagn Pathol* 2014 Sep;31(5):427-40.
<http://www.ncbi.nlm.nih.gov/pubmed/25129544>
392. Ulbright TM, Srigley JR, Reuter VE, et al. Sex-cord-stromal tumours of the testis with entrapped germ cells: a lesion mimicking unclassified mixed germ cell sex cord-stromal tumors. *Am J Surg Pathol* 2000 Apr;24(4):535-42.
<http://www.ncbi.nlm.nih.gov/pubmed/10757400>
393. Klotz T, Schwindl B, Mathers MJ. [Carcinoma of the rete testis with lymphogenous metastasis: multimodal treatment]. *Urologe A* 2012 Mar;51(3):409-11. [Article in German].
<http://www.ncbi.nlm.nih.gov/pubmed/22282103>

11. CONFLICT OF INTEREST

All members of the Testicular Cancer Guidelines working group have provided disclosure statements of all relationships that they have that might be perceived as a potential source of a conflict of interest. This information is publically accessible through the European Association of Urology website: <http://www.uroweb.org/guidelines/online-guidelines/>. This guidelines document was developed with the financial support of the European Association of Urology. No external sources of funding and support have been involved. The EAU is a non-profit organisation and funding is limited to administrative assistance and travel and meeting expenses. No honoraria or other reimbursements have been provided.